

Research paper

## *Galium aparine* L. protects against acetaminophen-induced hepatotoxicity in rats

Bilal Sahin<sup>a</sup>, Sebahattin Karabulut<sup>b,\*</sup>, Ahmet Kemal Filiz<sup>a</sup>, Mustafa Özkaraca<sup>c</sup>, Arzu Gezer<sup>d</sup>, Hüseyin Aşkın Akpulat<sup>e</sup>, Hilmi Ataseven<sup>f</sup>

<sup>a</sup> Department of Medical Physiology, Faculty of Medicine, Sivas Cumhuriyet University, Sivas, Turkey

<sup>b</sup> Department of Medical Services and Techniques, Vocational School of Health Services, Sivas Cumhuriyet University, Sivas, Turkey

<sup>c</sup> Department of Veterinary Pathology, Faculty of Veterinary Medicine, Sivas Cumhuriyet University, Sivas, Turkey

<sup>d</sup> Department of Health Care Services, Vocational School of Health Services, Ataturk University, Erzurum, Turkey

<sup>e</sup> Department of Biology, Faculty of Education, Cumhuriyet University, Sivas, Turkey

<sup>f</sup> Department of Internal Medicine, Discipline of Gastroenterology, Faculty of Medicine, Sivas Cumhuriyet University, Sivas, Turkey



## ARTICLE INFO

## Keywords:

Acetaminophen  
Acute hepatotoxicity  
Galium aparine  
Rat

## ABSTRACT

The toxicity of acetaminophen (N-acetyl-para-aminophenol (APAP)) is the most frequent cause of drug-induced liver damage. *Galium aparine* L. (GA) is traditionally used to treat jaundice. We aimed to investigate the hepatoprotective potential of GA in the APAP-induced hepatic encephalopathy (HE) rat model. Qualitative phytochemical characterization of GA was performed by LC/Q-TOF/MS analysis. Wistar rats were pretreated with GA (250 and 500 mg/kg b.wt. per oral) for five days. On the 6th day, the rats were exposed to APAP (1500 mg/kg b.wt. oral gavage) and behavioral tests (open field and passive avoidance tests) were applied on the 7th and 8th days. The animals were killed, and biochemical and histopathological parameters were assessed in blood and hepatic specimens. GA pretreated rats exhibited a significant reduction in APAP-induced liver damage, evidenced by the reduction in liver necrosis and alanine aminotransferase (ALT), aspartate aminotransferase (AST), and bilirubin (BIL). GA demonstrated an anxiolytic effect, as seen in the acquisition trial and grooming behavior. The short-term memory performances of animals were not changed in all groups, suggesting that APAP intoxication did not affect hippocampal function. These results show that GA extract markedly exerts hepatoprotective activity, while its effect on hepatic encephalopathy was limited.

## 1. Introduction

Acetaminophen (N-acetyl-para-aminophenol (APAP)) is one of the most widely used over-the-counter drugs to treat pain and fever. However, APAP toxicity is one of the common causes of drug-induced liver damage and acute liver failure, making it a significant public health concern [1]. Despite being considered safe in therapeutic doses, APAP can lead to severe hepatic necrosis in cases of deliberate or accidental overdose [2].

At the therapeutic doses, APAP is primarily metabolized in the liver via the processes of glucuronidation and sulfation to nontoxic metabolites, while a residual small fraction is metabolized by the cytochrome

P450 (CYP450) system to form a chemically reactive metabolite, n-acetyl-pbenzoquinoneimine (NAPQI) [3]. NAPQI then reacts with glutathione (GSH), an intracellular natural antioxidant, forming non-toxic conjugates that will be excreted [4]. However, when APAP is taken in high doses, it causes the rise of toxic NAPQI generation which depletes hepatic GSH levels, and as a result, leading to necrotic cell death in the liver [5]. It has been suggested that APAP-induced hepatic injury is characterized by some pathological cellular changes including oxidative stress, DNA fragmentation, and mitochondrial dysfunction in the liver [6]. Moreover, hepatocellular dysfunction impairs the clearance of ammonia via the urea cycle in the liver, leading to its accumulation in the brain at toxic levels, an ailment known as hepatic

**Abbreviations:** APAP, Acetaminophen; GA, Galium aparine L.; HE, Hepatic encephalopathy; AST, Aspartate aminotransferase; ALT, Alanine aminotransferase; BIL, Bilirubin; CYP450, Cytochrome P450; NAPQI, N-acetyl-pbenzoquinoneimine; GSH, Glutathione; GC/MS, Gas Chromatography/Mass Spectrometry; LC-Q-TOF-MS, Quadrupole time of flight mass spectrometry.

\* Corresponding author. Department of Medical Services and Techniques, Vocational School of Health Services, Sivas Cumhuriyet University, Sivas, Turkey.

E-mail address: [sbkarabulut@cumhuriyet.edu.tr](mailto:sbkarabulut@cumhuriyet.edu.tr) (S. Karabulut).

<https://doi.org/10.1016/j.cbi.2022.110119>

Received 22 June 2022; Received in revised form 8 August 2022; Accepted 16 August 2022

Available online 24 August 2022

0009-2797/© 2022 Elsevier B.V. All rights reserved.

**Table 1**

Compounds detected in Galium aparine methanolic extract obtained by LC-Q-TOF-MS.

Peak No	Retention Time (min)	Molecular Formula	m/z	Compound
1	1.733	C <sub>7</sub> H <sub>12</sub> O <sub>6</sub>	191,0555	Quinic acid
2	2.135	CHO	147,0287	Citramalic acid
3	3.206	C <sub>13</sub> H <sub>16</sub> O <sub>10</sub>	331,0672	1-O-Galloyl-beta-D-glucose
4	3.844	C <sub>10</sub> H <sub>6</sub> O <sub>4</sub>	193,0505	5,7-Dihydroxy-4-Methylcoumarin
5	3.875	C <sub>16</sub> H <sub>22</sub> O <sub>11</sub>	389,1077	Monotropein
6	7.356	C <sub>16</sub> H <sub>18</sub> O <sub>9</sub>	353,0881	Chlorogenic acid
8	11.238	C <sub>16</sub> H <sub>18</sub> O <sub>9</sub>	353,0871	Chlorogenic acid isomer
9	12.309	C <sub>33</sub> H <sub>40</sub> O <sub>21</sub>	771,1986	Quercetin Derivative
10	14.384	C <sub>16</sub> H <sub>18</sub> O <sub>8</sub>	337,0933	p-coumaroyl quinic acid
11	19.805	C <sub>27</sub> H <sub>30</sub> O <sub>16</sub>	609,1466	Rutin
12	25.427	C <sub>15</sub> H <sub>10</sub> O <sub>6</sub>	285,0405	Luteolin
13	25.762	C <sub>11</sub> H <sub>12</sub> O <sub>4</sub>	207,0659	Dimethylcaffeic acid
14	26.601	C <sub>15</sub> H <sub>10</sub> O <sub>5</sub>	271,0599	Apigenin

encephalopathy (HE) [7]. Earlier studies showed that HE caused by acute hepatic damage occurs following an overdose of APAP in both rats and humans [8], rats [9], and mice [10]. HE is characterized by psychiatric, cognitive, and motor disorders, and the synergistic relationship between ammonia, inflammation, and oxidative stress in its pathogenesis are well known [11–13]. Importantly, HE is associated with a high healthcare burden because of frequent hospitalization, and contributes significantly to impaired quality of life, morbidity, and mortality [14].

*Galium aparine* L. (GA) is an annual plant of the Rubiaceae family. The Galium genus has been widely represented in Turkey by 101 species [15]. In Anatolia, Galium species are known as “Yogurt herb” due to traditionally used to coagulate milk during manufacturing cheese. GA is also used in folk medicine to treat lymph swellings, fever, cancer, hypertension, gout, epilepsy, and wound healing [16,17]. Moreover, it has been reported that some galium species are used to treat hepatitis and jaundice [18–20]. It is noteworthy that GA is widely used to treat jaundice [21,22]. Khan et al. reported that a mixture of GA, *Berberis lycium*, and *Pistacia integerrima* have hepatoprotective effects in carbon tetrachloride-treated rats [23]. Phytochemical investigations revealed that the bioactive components of GA are tannins, polyphenolic acids, alkanes, iridoids, anthraquinone, flavonoids, and vitamin C [16]. Previous in-vitro and in-vivo studies revealed that different extracts of GA have antimicrobial, antioxidant, immunomodulatory, and anticancer

effects [16,17,24,25]. Based on the above-established reports on the radical scavenging and immunomodulatory effects of the natural antioxidant compounds found in the GA, it is reasonable to suggest that it may contribute to the significant hepatoprotective activity. Therefore, this study aimed to investigate the hepatoprotective potential of GA in the APAP-induced HE rat model.

## 2. Materials and methods

### 2.1. Plant material

*Galium aparine* L. plants at the flowering stage were collected from nearby Yapıdac village, Ezine district, June 06, 2019, (50–100 m), Çanakkale, Turkey. The taxonomic identification of plant materials was confirmed by a senior plant taxonomist, H. Aşkın Akpulat, in the Department of Biology, Cumhuriyet University, Sivas, Turkey. Due to its unique nature, we conducted our research with a careful collection, thereby using limited material in order to avoid causing damage to this species. The voucher specimen has been deposited at the Herbarium of the Department of Biology, Cumhuriyet University, Sivas-Turkey (CUFH-Voucher nos. AA 7390 respectively).

The extraction process was carried out as follows: The dried plant was milled to pass through a 200 µm diameter sieve by means of a hammer mill. The powder (100 g) was extracted in 500 g 65% ethanol and kept in the dark environment at room temperature for 14 days after contacting all parts of the plant with the solvent at an equal level. Afterward, the mixture was filtered with a vacuum filtration system and then the supernatant was filtered through a 0.42 µm paper filter to obtain clear GA extract. Finally, the ethanol in the extract was removed by the rotary evaporation process and concentrated GA extract was obtained. The final concentrate of the extract was 60 mg/mL.

### 2.2. Phytochemical analysis by LC/QTOF/MS

Using a similar method described previously [16], the GA extract was dissolved with methanol:water (80:20) mixture, it was filtered with a 0.45 mm membrane filter, and tested directly by LC/QTOF-MS (Agilent Accurate Mass 6530). (Table 1).

### 2.3. GC-MS analysis

GC-mass spectrometry (GC-MS-QP2010 Ultra; Shimadzu Corporation, Kyoto, Japan) was used to identify phytochemical compounds. The determination of the structure of the compounds was undertaken using

**Table 2**

GC/MS analysis of GA methanolic extract. The table reports the most abundant identified compounds in retention time (tR) order. Interpretation of mass spectrum of GC-MS was conducted using the database of W10N14 and given as % similarity.

Compound	Retention Time (min)	Molecular weight	Molecular Formula	W10N14 match (similarity, %)
N-Methoxy-N-methylacetamide	4.180	103	C <sub>4</sub> H <sub>9</sub> NO <sub>2</sub>	90
2-Propenoic acid, methyl ester	4.624	86	C <sub>4</sub> H <sub>6</sub> O <sub>2</sub>	84
1,2,3-Propanetriol (CAS)	5.057	92	C <sub>3</sub> H <sub>8</sub> O <sub>3</sub>	91
Methyl 2-Oxopropanoate	5.762	102	C <sub>10</sub> H <sub>8</sub> O <sub>4</sub>	95
2-Furanmethanol	7.968	98	C <sub>5</sub> H <sub>6</sub> O <sub>2</sub>	95
2(3H)-Furanone, dihydro-	9.970	86	C <sub>4</sub> H <sub>6</sub> O <sub>2</sub>	91
2(5H)-Furanone	10.028	84	C <sub>4</sub> H <sub>4</sub> O <sub>2</sub>	86
6-Oxa-bicyclo [3.1.0] hexan-3-one	10.459	98	C <sub>5</sub> H <sub>6</sub> O <sub>2</sub>	89
2-acetyl-2-hydroxy-γ-butyrolactone	17.843	144	C <sub>6</sub> H <sub>8</sub> O <sub>4</sub>	84
4H-Pyran-4-one, 2,3-dihydro-3,5-dihydroxy-6-methyl-	18.121	144	C <sub>6</sub> H <sub>8</sub> O <sub>4</sub>	93
1,2-Benzenediol	19.983	110	C <sub>6</sub> H <sub>6</sub> O <sub>2</sub>	88
2-Furancarboxaldehyde, 5-(Hydroxymethyl)-	20.745	126	C <sub>6</sub> H <sub>6</sub> O <sub>3</sub>	81
2-Methoxy-4-vinylphenol	23.258	150	C <sub>9</sub> H <sub>10</sub> O <sub>2</sub>	81
2-Propenoic acid, 3-(3,4-dihydroxyphenyl)-	26.731	180	C <sub>9</sub> H <sub>8</sub> O <sub>4</sub>	77
Hexadecanoic acid	38.786	256	C <sub>6</sub> H <sub>6</sub> O <sub>3</sub>	90
Hexadecanoic acid, ethyl ester	39.438	284	C <sub>18</sub> H <sub>36</sub> O <sub>2</sub>	82
9-Octadecynoic acid	42.698	280	C <sub>18</sub> H <sub>32</sub> O <sub>2</sub>	87
11,14,17-Eicosatrienoic acid, methyl ester	42.830	320	C <sub>21</sub> H <sub>36</sub> O <sub>2</sub>	87
9-Octadecenamide		281	C <sub>18</sub> H <sub>35</sub> NO	92

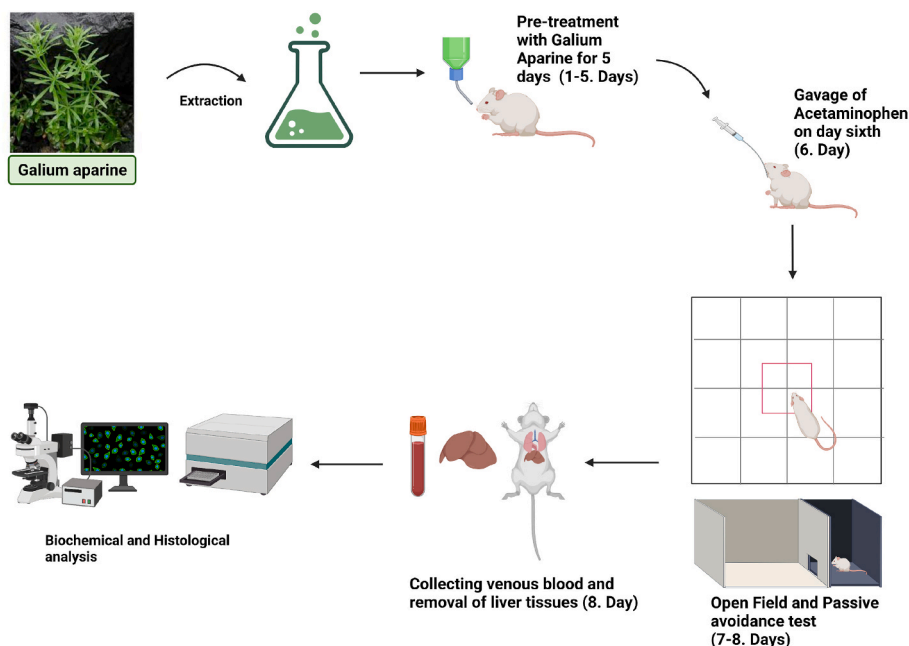


Fig. 1. Experimental design of the study (created with BioRender.com).

Wiley 10th/NIST 2014 mass spectral library (W10N14; John Wiley & Sons, Hoboken, NJ, USA), reference specimen, or spectra interpretation. The compounds defined by GC-MS in the GA MeOH extract sample are presented in Table 2.

## 2.4. Drugs

Parol 500 mg (Atabay, Turkey) pills and Sodium Chloride 0.9% (Polifarma, Turkey) were purchased from the public pharmacy.

## 2.5. Experimental animals and treatment

The experimental procedures used in this study were approved by the Institutional Animal Ethical Committee (Approval no: 65202830-050.04.04-563). The Wistar albino rats (body weight ~250 gr, male, normal chow) were purchased from the Cumhuriyet University Animal Laboratory, Sivas, Turkey. The GA extracts were added to the water bottles considering the daily water consumption of animals (30 ml/day) [26]. The animals were randomly divided into four groups (6 rats per group) and treated as follows:

- (1) Control group; rats that drank only tap water.
- (2) APAP group; rats that drank tap water for five days, received a single dose of APAP per oral (p.o.) on day six.
- (3) GA-250 group; rats that drank tap water containing 250 mg/kg of extract of GA for five days and received a single dose of APAP with p.o. on day six.
- (4) GA-500 group; rats that drank tap water containing 500 mg/kg of extract of GA for five days and received a single dose of APAP with p.o. on day six.

To examine the protective effect of GA (groups GA-250 and GA-500), animals were pretreated with GA for 5 consecutive days. Acute hepatotoxicity in rats was induced by a single dose of APAP at a dose level of 1500 mg/kg body weight dissolved in saline on the sixth day by oral gavage [27]. The rats were starved for 15–16 h before APAP administration [28]. Animals' locomotor activity and cognitive performance were assessed 24 h after APAP treatment. After the rats were killed by cervical dislocation, blood and liver samples were collected. The experimental protocol of the research is presented in Fig. 1.

## 2.6. Animal behavioral tests

### 2.6.1. Open-field test

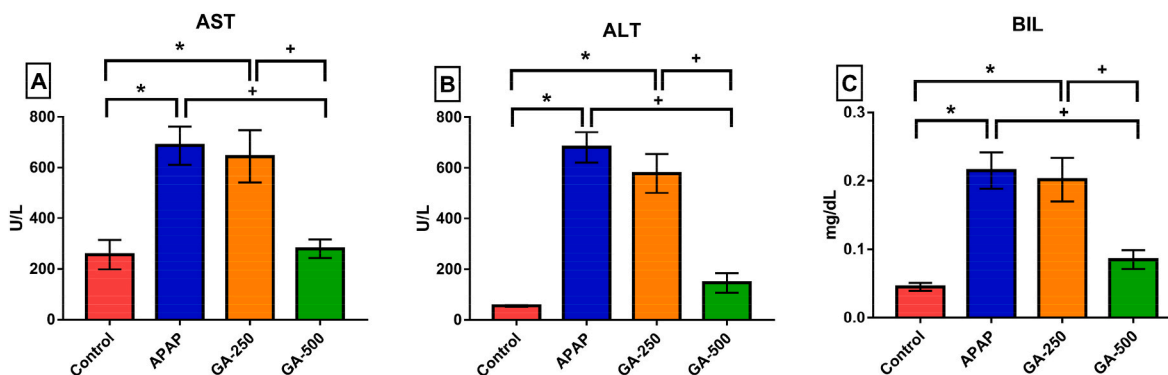
The open field test provides an indication of the animal's locomotor activity in an animal model of hyperammonemia and HE. This test also provides information about the emotional state of the animals. The apparatus, which consists of a square area divided by 16 small units (100 cm × 100 cm x 30 cm), allows rats to move freely in the arena for 5 min. While the total number of passed units reflects the level of locomotor activity, the number of grooming is expressed as fear states, and the exploratory activity is defined as the total rearing number [29].

### 2.6.2. Passive avoidance test

The passive avoidance task includes a fear-exacerbated procedure assessing rodents' emotional learning with short- or long-term memory. The apparatus consists of two chambers, one lighted and the other dark distinguished by an automatically retractable gate. The floors of the two rooms the compose of stainless steel rods. In acquisition trial, rats gently place to light chamber and after 10 s, the door opens. Because of the rodents have an innate preference for the dark and enclosed environment, the animal spontaneously walks into the dark part of the apparatus. When the animal enters the dark chamber, the door is shut and the animal is punished with single low intensity foot shock of 0.5 mA for 5 s, followed by recording of time latencies. After a 24-h period, retention trial is performed to assess the passive avoidance memory of the rats by step-through latency. This is the same procedure as the acquisition trial, except that no shock punishment is given to the animals when they enter the dark compartment. The criterion for learning is considered an increase in the time latency on the retention trial in comparison with to acquisition trial [30].

## 2.7. Biochemical assays

After the blood samples were taken from the inferior vena cava, they were centrifuged at 3000 rpm for 10 min. The serum levels of alanine aminotransferase (ALT), aspartate aminotransferase (AST), and total bilirubin (BIL) levels were measured with an automated spectrophotometric analyzer (Thermo Fisher Scientific, Altrincham, UK). Values were expressed in U/L.



**Fig. 2.** Effect of pretreatment GA (250 mg/kg and 500 mg/kg, p.o.) on serum AST, ALT, and BIL in APAP (1500 mg/kg, i.p.) acutely intoxicated rats. The data represent the means  $\pm$  SEM. (n = 6 per group) (\* $p$  < .05, compared to the control group; + $p$  < .05, compared to the GA-500 group).

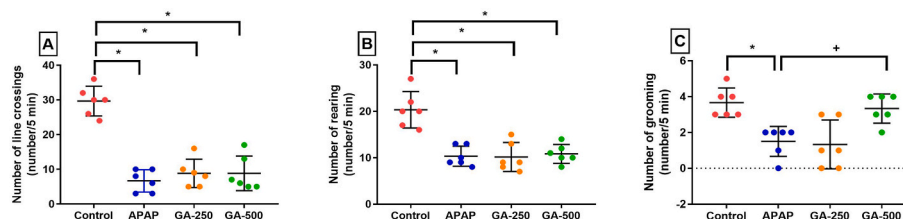
## 2.8. Histopathological and immunohistochemical evaluation

Liver samples from necropsy rats were fixed in a 10% neutral formalin solution. Tissues were taken into paraffin blocks after routine tissue procedures follow-up. Afterward, 5  $\mu$  tissue sections were stained with hematoxylin-eosin (H-E). Tissue sections were evaluated under a light microscope as absent (–), mild (+), moderate (++) , severe (+++), and very severe (++++ ) in terms of necrosis, hemorrhage, and mononuclear cell infiltration.

Using a similar method described previously [31], 5  $\mu$ m tissue sections taken on polylysine slides were passed through the xylol and alcohol series, washed with PBS, and then kept in 3% H<sub>2</sub>O<sub>2</sub> for 10 min to inactivate endogenous peroxidase. It was treated with antigen elimination solution for 2  $\times$  5 minutes at 500 W to reveal the antigen in the tissues. After the protein block was applied, the tissues washed with PBS were incubated with 8-OHdG (Santa Cruz, Cat no. sc-66036) and gamma H2AX (Abcam, Catalog no. ab26350) primary antibodies at 1/200 dilution at room temperature for 45 min. Following staining with Mayer Hematoxylin, it was coated with entellan, and then the samples were examined under light microscopy. In the examination, immunopositivity was assessed as follows: absent (–), mild (+), moderate (++) , severe (+++).

## 2.9. Statistical analysis

Results were expressed as mean  $\pm$  standard error of the mean (SEM). The Shapiro-Wilk test was performed to determine if the data were normally distributed. Groups of data were compared with one-way ANOVA followed by Tukey's multiple comparison tests. For histopathological examinations, the differences between the groups were determined by the Kruskal-Wallis test and the different groups were determined by the Mann-Whitney *U* test. Differences were considered statistically significant at the level of  $p$  < .05. Statistical analysis was conducted using the Graph Pad Prism software version 7 (GraphPad Software, Inc., San Diego, CA, USA).



**Fig. 3.** Effect of pretreatment GA (250 mg/kg and 500 mg/kg, p.o.) on number of line crossings, rearing and grooming in APAP (1500 mg/kg, i.p.) acutely intoxicated rats. The data represent the mean  $\pm$  SEM. (n = 6 per group) (\* $p$  < .05, compared to the control group; + $p$  < .05, compared to the GA-500 group).

## 3. Results

### 3.1. Phytochemical identification of GA extract by LC/Q-TOF/MS assay

Biologically active complexes were determined by conducting qualitative phytochemical assay of GA MEOH extracts. Under the current chromatographic/MS conditions, a total of 14 phytochemicals; Quinic acid, Citramalic acid, 1-O-Galloyl-beta-D-glucose, 5,7-Dihydroxy-4-Methylcoumarin, Monotropein, Chlorogenic acid, Quercetin derivative, p-coumaroyl quinic acid, Rutin, Luteolin, Dimethylcaffeic acid, and Apigenin were identified (Table 2).

### 3.2. The effect of GA extract on serum liver functions in APAP-induced HE in rats

Serum AST, ALT, and BIL levels were measured to estimate hepatocellular damage. APAP treatment alone increased serum AST levels from  $256 \pm 57.95$  to  $686 \pm 75.06$  U/L ( $P = .0023$ , Fig. 2A), serum ALT levels from  $56 \pm 3.94$  to  $680.8 \pm 59.59$  U/L ( $P = .0001$ , Fig. 2B) and serum BIL levels from  $0.045 \pm 0.005$  to  $0.215 \pm 0.026$  mg/dL ( $P = .0001$ , Fig. 2C) compared to controls; it implied that APAP caused liver dysfunction and signified the injury to hepatocytes. However, pretreatment of APAP-induced HE rats with GA (500 mg/kg) showed a significant reduction in serum AST levels from  $686 \pm 75.06$  to  $279.7 \pm 36.19$  U/L (APAP vs GA-500,  $P = .0038$ , Fig. 2A), serum ALT levels from  $680.8 \pm 59.59$  to  $146.2 \pm 38.12$  U/L (APAP vs GA-500,  $P = .0001$ , Fig. 2B), and serum BIL levels from  $0.215 \pm 0.026$  to  $0.085 \pm 0.0138$  mg/dL (APAP vs GA-500,  $P = .0025$ , Fig. 2C). Likewise, the decrease in serum AST (from  $643 \pm 102.9$  to  $279.7 \pm 36.19$  U/L; GA-250 vs GA-500,  $P = .0097$ , Fig. 2A), serum ALT (from  $577.8 \pm 77.42$  to  $146.2 \pm 38.12$  U/L; GA-250 vs GA-500,  $P = .0001$ , Fig. 2B), and serum BIL from  $0.202 \pm 0.032$  to  $0.085 \pm 0.0138$  mg/dL (GA-250 vs GA-500,  $P = .0067$ , Fig. 2C) levels after pretreatment of GA 500 mg/kg was statistically significant compared to pretreatment of GA 250 mg/kg.

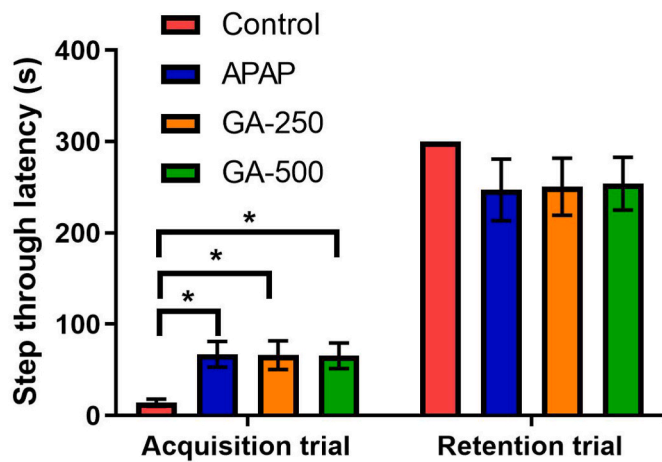


Fig. 4. Effect of pretreatment of GA (250 mg/kg and 500 mg/kg, p.o.) on memory performance during the passive avoidance test in APAP (1500 mg/kg, i.p.) acutely intoxicated rats. The data represent the mean  $\pm$  SEM. (n = 6 per group) (\*p < .05, compared to the control group).

Table 3  
Histopathological injury markers in liver tissues of the groups.

Groups	Hemorrhage	Mononuclear cell infiltration	Necrosis
Control	0,16 $\pm$ 0,40 <sup>a</sup>	0,16 $\pm$ 0,40 <sup>a</sup>	0,33 $\pm$ 0,40 <sup>a</sup>
APAP	2,83 $\pm$ 0,40 <sup>b</sup>	3,00 $\pm$ 0,00 <sup>b</sup>	2,83 $\pm$ 0,40 <sup>b</sup>
GA-250	2,66 $\pm$ 0,51 <sup>b</sup>	2,66 $\pm$ 0,51 <sup>b</sup>	2,83 $\pm$ 0,40 <sup>b</sup>
GA-500	1,16 $\pm$ 0,40 <sup>c</sup>	1,83 $\pm$ 0,40 <sup>c</sup>	1,00 $\pm$ 0,00 <sup>c</sup>

<sup>a,b,c</sup> indicates the difference between groups (p < .05).

### 3.3. The effect of GA extract on behavioral parameters in APAP-induced HE in rats

Locomotor activities (number of line crossed) and anxiety levels

(grooming and rearing) of animals were assessed by open field test. Animals' locomotor activity was significantly reduced in the APAP group from  $29.67 \pm 1.745$  to  $6.677 \pm 1.308$  number/5 min (Control vs APAP, P = .0001), GA-250 group from  $29.67 \pm 1.745$  to  $8.833 \pm 1.662$  number/5 min (Control vs GA-250, P = .0028) and GA-500 group from  $29.67 \pm 1.745$  to  $8.833 \pm 2.04$  number/5 min (Control vs GA-500, P = .0027) (Fig. 3A). Similarly, the number of rearing was remarkably decreased in the APAP group from  $20.33 \pm 1.606$  to  $10.33 \pm 0.882$  number/5 min (Control vs APAP, P = .0078), GA-250 group from  $20.33 \pm 1.606$  to  $10.17 \pm 1.276$  number/5 min (Control vs GA-250, P = .0071) and GA-500 group from  $20.33 \pm 1.606$  to  $10.83 \pm 0.833$  number/5 min (Control vs GA-500, P = .0219) (Fig. 3B). The number of grooming was significantly decreased in APAP-treated animals from  $3.667 \pm 0.333$  to  $1.5 \pm 0.345$  number/5 min (Control vs APAP, P = .0110), while it was significantly increased in animals pretreated with 500 mg GA from  $1.5 \pm 0.345$  to  $3.333 \pm 0.333$  number/5 min (APAP vs GA-500, P = .0219) (Fig. 3C)

The learning/memory abilities of the animals were evaluated by the passive avoidance test. Interestingly, the latency of rats moving from the light chamber to the dark chamber on the first day was nearly the same in all APAP-treated groups ( $68.83 \pm 13.31$  s,  $66.17 \pm 15.51$  s, and  $65.50 \pm 13.85$  s; in APAP, GA-250, and GA-500 groups, respectively), and it was significantly different from the Control group ( $14.4 \pm 4$  s) (P = .0026, P = .0036, P = .0032; APAP, GA-250, and GA-500 compared to Control group, respectively). In contrast, no significant difference was found between the groups in terms of the latency of moving from the light chamber to the dark chamber in the shuttle box, after being exposed to an electrical shock ( $300 \pm 0.0$  s,  $247.16 \pm 33.6$  s,  $250.67 \pm 31.28$  s, and  $254.33 \pm 28.9$  s; in Control, APAP, GA-250, and GA-500 groups, respectively) (Fig. 4).

### 3.4. The effect of GA extract on APAP-induced liver histopathological and immunohistochemical alterations

Statistically significant differences were found between the groups in histopathological examinations (Table 3, p < .05). The control group

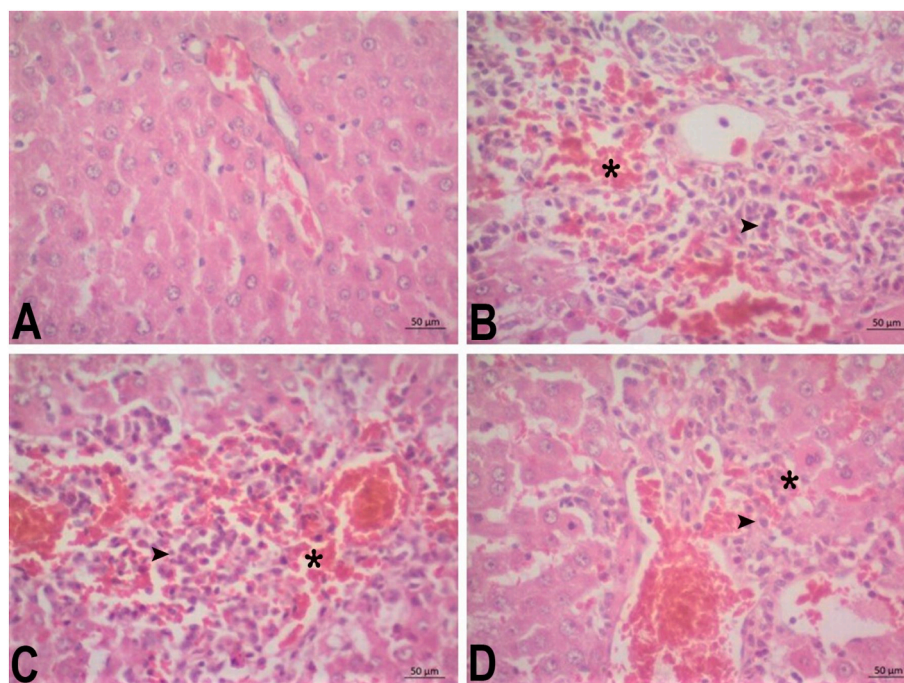
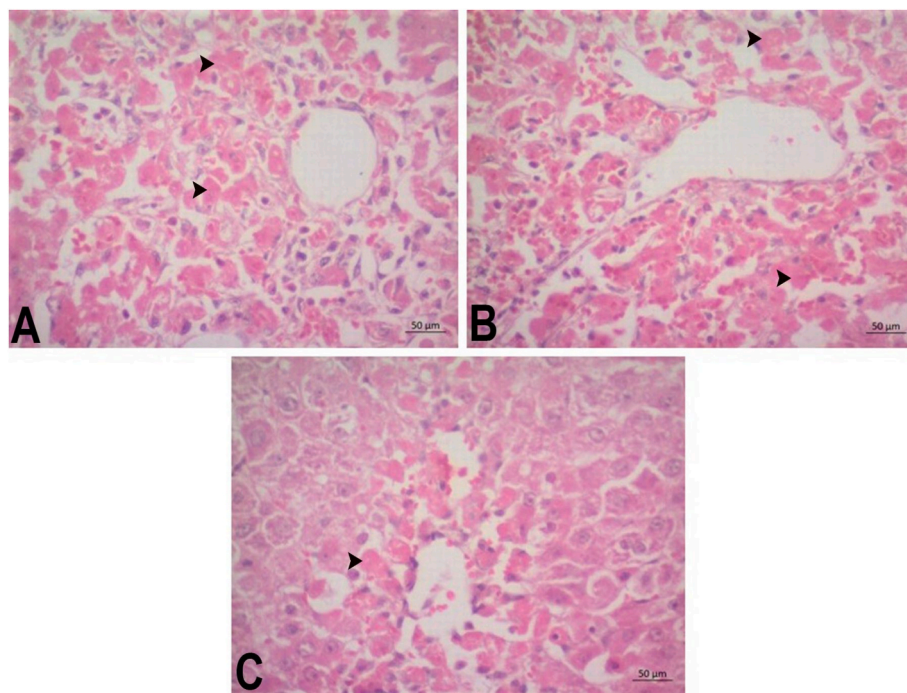


Fig. 5. Effect of pretreatment of GA (250 mg/kg and 500 mg/kg, p.o.) on liver histopathology in APAP (1500 mg/kg, i.p.) acutely intoxicated rats. A) Control group, normal histological appearance. B) APAP group, severe hemorrhage (\*) and mononuclear cell infiltration (arrowhead). C) GA-250 group, severe hemorrhage (\*) and mononuclear cell infiltration (arrowhead), D) GA-500 group, mild hemorrhage (\*) and moderate mononuclear cell infiltration (arrowhead). H-E.



**Fig. 6.** Effect of pretreatment of GA (250 mg/kg and 500 mg/kg, p.o.) on liver histopathology in APAP (1500 mg/kg, i.p.) acutely intoxicated rats. A) APAP group. Severe necrotic hepatocytes (arrowhead). B) GA-250 group. Severe necrotic hepatocytes (arrowhead). C) GA-500 group. Mild necrotic hepatocytes (arrowhead). H-E.

**Table 4**

Immunohistochemical staining for 8-OHdG and Gamma H2AX in liver tissues of the study groups.

Groups	8-OHdG	Gamma H2AX
Control	0,33 ± 0,40 <sup>a</sup>	0,16 ± 0,40 <sup>a</sup>
APAP	2,83 ± 0,40 <sup>b</sup>	2,16 ± 0,40 <sup>b</sup>
GA-250	2,66 ± 0,51 <sup>b</sup>	2,33 ± 0,51 <sup>b</sup>
GA-500	1,83 ± 0,40 <sup>c</sup>	1,16 ± 0,40 <sup>c</sup>

<sup>a,b,c</sup> indicates the difference between groups ( $p < .05$ ).

had a normal histological appearance. Severe hemorrhage, mononuclear cell infiltrations, and necrosis were observed in the APAP and GA-250 groups, whereas mononuclear cell infiltrations were moderate, hemorrhage and mononuclear cell infiltrations were mild in the GA-500 group (Figs. 5–6).

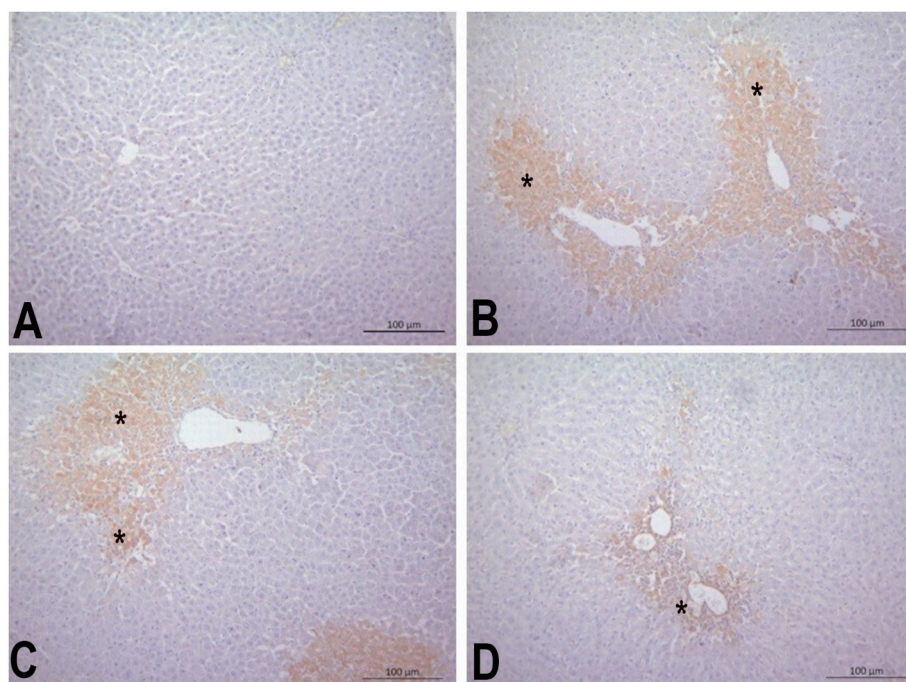
Statistically significant differences were found between the groups in immunohistochemical staining for 8-OHdG and Gamma H2AX (Table 4,  $p < .05$ ). Significant 8-OHdG and Gamma H2AX immunopositivity could not be detected in the control group. While 8-OHdG immunopositivity was severe in the APAP and GA-250 groups, it was moderate in the GA-500 group. Gamma H2AX immunopositivity was moderate in the APAP and GA-250 groups and mild in the GA-500 group. 8-OHdG and Gamma H2AX immunopositivity were in hepatocytes surrounding the vena centralis (Figs. 7–8).

#### 4. Discussion

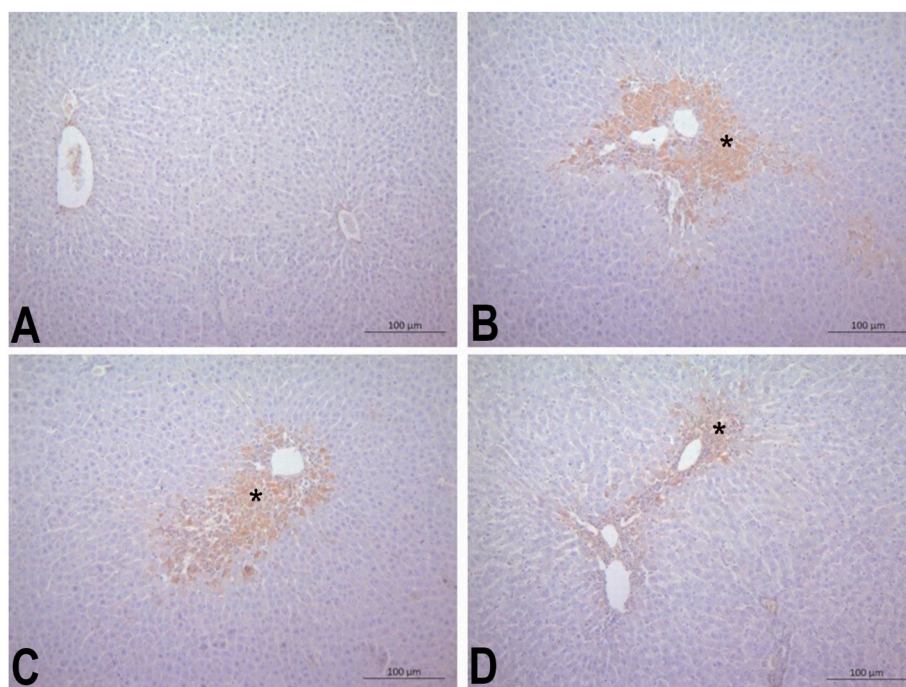
This study sought to investigate the potential beneficial effect of GA using the APAP-induced HE rat model as a well-established pharmacologically-induced hepatotoxicity model. The current study's findings revealed that pretreatment of GA produces protective effects on APAP-induced hepatotoxicity by improving the serum levels of liver enzymes and liver histology changes in rats. However, the therapeutic effect of GA pretreatment on impaired behavioral parameters induced by APAP remained limited. Overall, these findings imply that GA has a hepatoprotective effect.

The serum concentration of transaminase enzymes such as AST and ALT is often used as a biomarker of hepatic necrosis [32]. Previous studies showed that APAP overdose leads to liver damage resulting in higher serum levels of ALT, AST, and BIL [33–37]. Our results corroborate these findings because APAP has led to profound liver damage, as indicated by elevated liver enzymes AST and ALT and high serum BIL levels. All these results indicate hepatocyte membrane disruption caused by high APAP, which leads to cellular leakage, including ALT and AST, and high levels of these enzymes. Similar hepatotoxic effects caused by APAP intoxication were also obtained in our histopathological observations characterized by necrotic cells and oxidative DNA damage accompanied by 8-OHdG and gamma-H2AX immunopositivity, which are markers of DNA damage and thus cell death [38,39]. However, when GA (especially in high dose) was administered before a high dose of APAP, it reversed these changes in biochemical and histological parameters suggesting it effectively protected APAP-induced hepatic damage. This protective ability of GA extract against hepatotoxicity can be explained by the phytochemicals in its content, such as quercetin, rutin, luteolin, apigenin, and quinic acid [40–43]. Domitrović et al. demonstrated that rutin and quercetin can ameliorate CCl<sub>4</sub>-induced acute liver damage [40]. Similarly, Pan et al. reported that rutin attenuates bile duct ligation-induced hepatic fibrosis, inflammation, and oxidative stress [44]. Luteolin, a flavone, has been shown to protect against GalN/LPS-induced hepatotoxicity through the regulation of inflammatory mediators and phase II enzymes [41]. Another flavonoid, apigenin, mitigated liver injury by ameliorating inflammation and oxidative stress through suppression of the non-canonical NF-κB pathway [42]. Overall, these observations suggest that GA, rich in the above flavonoids, may be a therapeutic agent for liver damage.

In behavioral studies, it was observed that the administration of APAP caused different results on the acquisition and retention days of the passive avoidance test. Interestingly, animals in all groups treated with APAP were reluctant to enter the dark side of the chamber, which was manifested by an increase in latency time in the acquisition trial. As far as we know, APAP has never been reported to have caused such an effect on passive avoidance testing. Since rodents have an innate preference for dark and enclosed environments [45], this behavioral



**Fig. 7.** Effect of pretreatment of GA (250 mg/kg and 500 mg/kg, p.o.) on liver histopathology in APAP (1500 mg/kg, i.p.) acutely intoxicated rats. A) Control group. 8-OHdG immunonegativity. B) APAP group. Severe 8-OHdG immunopositivity (\*). C) GA-250 group. Severe 8-OHdG immunopositivity (\*). D) GA-500 group. Moderate 8-OHdG immunopositivity (\*). IHC.



**Fig. 8.** Effect of pretreatment of GA (250 mg/kg and 500 mg/kg, p.o.) on liver histopathology in APAP (1500 mg/kg, i.p.) acutely intoxicated rats. A) Control group. Gamma H2AX immunonegativity. B) APAP group. Moderate Gamma H2AX immunopositivity (\*). C) GA-250 group. Moderate Gamma H2AX immunopositivity (\*). D) GA-500 group. Mild Gamma H2AX immunopositivity (\*). IHC.

disorder points to the devastating effect of APAP intoxication, defined as HE, on the central nervous system. However, no significant difference between groups in the retention trial implies that the short-term memory functions of the animals are not impaired. The data regarding the effect of HE on the passive avoidance test performance of animals are inconsistent. Mendez et al. investigated the effect of Type B HE

(portacaval shunt) and Type C HE (cirrhosis by intoxication with thioacetamide), two experimental models of HE, on passive avoidance testing and reported that only Type B had a memory deficit [46]. In contrast, Hajipour et al. reported a memory deficit in the passive avoidance test in the thioacetamide-induced HE rat model [47]. This discrepancy may be due to the fact that the differences in the model of

HE and the experimental protocols. We propose that a possible explanation for our study's observed difference between acquisition and retention trials may be that different brain regions were affected. Passive avoidance learning involves contextual memory associated with the hippocampus and amygdala-dependent emotional memory [46]. The amygdala may be more damaged in the APAP-induced HE model, while the hippocampus may be relatively less affected. Our data show a significant decrease in locomotor activity in all APAP-treated rats. This observation is in accordance with that of Ommati et al., who reported that APAP-treated animals have lower open field activity [37]. Our findings also show that the pretreatment of GA reduces animals' anxiety levels, leading to an increase in grooming behavior. The compounds in the GA extract, such as apigenin and chlorogenic acid, which have anxiolytic effects, can explain this result [48,49].

In conclusion, this study demonstrates that GA pretreatment significantly protects against APAP-induced liver damage in a dose-dependent manner, as demonstrated by improvements in hepatic biochemical and histopathological parameters. However, it shows that GA pretreatment partially protects against APAP-induced HE, as demonstrated in behavioral outcomes. It is worth saying that the effect of GA on the brain is lower than its hepatic effects, which can be attributed to its ability to cross the blood-brain barrier partially. Future studies employing cellular and molecular techniques may help to identify and characterize putative pathway(s) involved in this protective effect, such as antioxidative, antiinflammatory, and antiapoptotic.

#### Author statement

Bilal Sahin: Conceptualization, Methodology. Sebahattin Karabulut: Data curation, Writing- Original draft preparation. Ahmet Kemal Filiz: Investigation. Mustafa Özkaraca: Reviewing and Editing. Arzu Gezer: Investigation. Hüseyin Aşkın Akpulat: Writing- Reviewing and Editing. Hilmi Ataseven: Supervision.

#### Declaration of competing interest

The authors declare that they have no known competing financial interests or personal relationships that could have appeared to influence the work reported in this paper.

#### Data availability

Data will be made available on request.

#### Acknowledgements

We would like to thank the Sivas Cumhuriyet University, School of Medicine, CUTFAM Research Center, Sivas, Turkey, and CÜTAM, Sivas, Turkey, for providing the necessary facilities to conduct this study.

#### Appendix A. Supplementary data

Supplementary data to this article can be found online at <https://doi.org/10.1016/j.cbi.2022.110119>.

#### References

- H.Z. Toklu, A.Ö. Şehirli, A. Velioğlu-Öğünç, Ş. Çetinel, G. Şener, Acetaminophen-induced toxicity is prevented by  $\beta$ -D-glucan treatment in mice, *Eur. J. Pharmacol.* 543 (2006) 133–140, <https://doi.org/10.1016/j.ejphar.2006.05.033>.
- A.N. Hamlyn, A.P. Douglas, O. James, The spectrum of paracetamol (acetaminophen) overdose: clinical and epidemiological studies, *Postgrad. Med. J.* 54 (1978) 400–404, <https://doi.org/10.1136/pgmj.54.632.400>.
- C.I. Ghanem, M.J. Pérez, J.E. Manautou, A.D. Mottino, Acetaminophen from liver to brain: new insights into drug pharmacological action and toxicity, *Pharmacol. Res.* 109 (2016) 119–131, <https://doi.org/10.1016/j.phrs.2016.02.020>.
- G.G. Graham, K.F. Scott, R.O. Day, Tolerability of paracetamol, *Drug Saf.* 28 (2012) 227–240, <https://doi.org/10.2165/00002018-200528030-00004>, 2005 283.
- Z.A. Zakaria, F.H. Kamisan, N.M. Nasir, L.K. Teh, M.Z. Salleh, Aqueous partition of methanolic extract of dicranopteris linearis leaves protects against liver damage induced by paracetamol, *Nutrients* 11 (2019), <https://doi.org/10.3390/NU11122945>.
- H. Jaeschke, M.L. Bajt, Intracellular signaling mechanisms of acetaminophen-induced liver cell death, *Toxicol. Sci.* 89 (2006) 31–41, <https://doi.org/10.1093/toxsci/kfi336>.
- S. DeMorrow, C. Cudalbu, N. Davies, A.R. Jayakumar, C.F. Rose, ISHEN guidelines on animal models of hepatic encephalopathy, *Liver Int.* 41 (2021) 1474–1488, <https://doi.org/10.1111/LIV.14911>, 2021.
- C. Bémeur, R.F. Butterworth, Liver-brain proinflammatory signalling in acute liver failure: role in the pathogenesis of hepatic encephalopathy and brain edema, in: *Metab. Brain Dis., Metab Brain Dis*, 2013, pp. 145–150, <https://doi.org/10.1007/s11011-012-9361-3>.
- M.A. Saad, A.A. Rastanawi, M.F. El-Yamany, Alogliptin abates memory injuries of hepatic encephalopathy induced by acute paracetamol intoxication via switching-off autophagy-related apoptosis, *Life Sci.* 215 (2018) 11–21, <https://doi.org/10.1016/j.lfs.2018.10.069>.
- Y.J. Fan, Y. Rong, P.F. Li, W.L. Dong, D.Y. Zhang, L. Zhang, M.J. Cui, Genistein protection against acetaminophen-induced liver injury via its potential impact on the activation of UDP-glucuronosyltransferase and antioxidant enzymes, *Food Chem. Toxicol.* 55 (2013) 172–181, <https://doi.org/10.1016/j.fct.2013.01.003>.
- D.L. Shawcross, N.A. Davies, R. Williams, R. Jalan, Systemic inflammatory response exacerbates the neuropsychological effects of induced hyperammonemia in cirrhosis, *J. Hepatol.* 40 (2004) 247–254, <https://doi.org/10.1016/j.jhep.2003.10.016>.
- C.R. Bosoi, X. Yang, J. Huynh, C. Parent-Robitaille, W. Jiang, M. Tremblay, C. F. Rose, Systemic oxidative stress is implicated in the pathogenesis of brain edema in rats with chronic liver failure, *Free Radic. Biol. Med.* 52 (2012) 1228–1235, <https://doi.org/10.1016/j.freeradbiomed.2012.01.006>.
- R. Cf, A. P, B. Js, D. Rk, M. S, T.-R. Sd, V. H, J. R, Hepatic encephalopathy: novel insights into classification, pathophysiology and therapy, *J. Hepatol.* 73 (2020) 1526–1547, <https://doi.org/10.1016/j.jhep.2020.07.013>.
- M. Stepanova, A. Mishra, C. Venkatesan, Z.M. Younossi, In-hospital mortality and economic burden associated with hepatic encephalopathy in the United States from 2005 to 2009, *Clin. Gastroenterol. Hepatol.* 10 (2012), <https://doi.org/10.1016/j.cgh.2012.05.016>.
- N. Orhan, D. Deliorman Orhan, M. Aslan, M. Ükürölu, I.E. Orhan, UPLC-TOF-MS analysis of Galium spurium towards its neuroprotective and anticonvulsant activities, *J. Ethnopharmacol.* 141 (2012) 220–227, <https://doi.org/10.1016/j.jep.2012.01.056>.
- H. Atmaca, E. Bozkurt, M. Cattan, H. Dilek, Tepe, Effects of Galium aparine extract on the cell viability, cell cycle and cell death in breast cancer cell lines, *J. Ethnopharmacol.* 186 (2016) 305–310, <https://doi.org/10.1016/j.jep.2016.04.007>.
- J. Bokhari, M.R. Khan, M. Shabbir, U. Rashid, S. Jan, J.A. Zai, Evaluation of diverse antioxidant activities of Galium aparine, *Spectrochim. Acta Part A Mol. Biomol. Spectrosc.* 102 (2013) 24–29, <https://doi.org/10.1016/j.saa.2012.09.056>.
- N. Kahkeshani, B. Farahaniki, P. Mahdavi, A. Abdolghaffari, G. Hassanzadeh, M. Abdollahi, M. Khanavi, Antioxidant and burn healing potential of Galium odoratum extracts, *Res. Pharm. Sci.* 8 (2013) 197. <https://doi.org/10.1016/j.rps.2013.12.001>. (Accessed 17 December 2021).
- A.K. Jan, I. Anis, M.R. Shah, I. Ahmad, Essential oil composition of galium asperifolium, *Chem. Nat. Compd.* 52 (2016) 512–513, <https://doi.org/10.1007/S10600-016-1692-6/TABLES/1>.
- D. Tewari, A. Mocan, E.D. Parvanov, A.N. Sah, S.M. Nabavi, L. Huminiecki, Z. F. Ma, Y.Y. Lee, J.O. Horbanczuk, A.G. Atanasov, Ethnopharmacological approaches for the therapy of jaundice: Part I, *Front. Pharmacol.* 8 (2017) 518, <https://doi.org/10.3389/fphar.2017.00518/BIBTEX>.
- A. Mehmood Abbasi, M. Ajab Khan, M.M. Shah, A. Pervez, M. Ahmad, Ethnobotanical Appraisal and Cultural Values of Medicinally Important Wild Edible Vegetables of Lesser Himalayas-Pakistan, 2013. <http://www.ethnobiomed.com/content/9/1/66>. (Accessed 17 December 2021).
- M. Adnan, D. Hlscher, Medicinal Plant Abundance in Degraded and Reforested Sites in Northwest Pakistan, 2010, pp. 25–32, <https://doi.org/10.1659/MRD-JOURNAL-D-09-00017.1>. <https://doi.org/10.1659/MRD-JOURNAL-D-09-00017.1>.
- M.A. Khan, J. Khan, S. Ullah, S. Malik, M. Shafi, HEPATOPROTECTIVE EFFECTS OF BERBERIS LYCIUM, GALIUM APARINE AND PISTACIA INTEGERRIMA IN CARBON TETRACHLORIDE (CCL4)-TREATED RATS, *Undefined*, 2011.
- O.V. Goryacha, T.V. Ilyina, A.M. Kovalyova, N.V. Kashpur, Phytochemical research of Galium aparine L. Lipophilic complex and study of its antibacterial activity, *Pharma Innov. J.* 3 (2014) 7–10. <https://www.thepharmajournal.com/archives/?year=2014&vol=3&issue=1&ArticleId=303>. (Accessed 4 October 2021).
- T. Ilina, N. Kashpur, S. Granica, A. Bazylko, I. Shinkovenko, A. Kovalyova, O. Goryacha, O. Koshovyi, Phytochemical profiles and in vitro immunomodulatory activity of ethanolic extracts from Galium aparine L, *Plants* 8 (2019), <https://doi.org/10.3390/plants8120541>.
- F. Nistiar, O. Racz, A. Lukacinova, B. Hubkova, J. Novakova, E. Lovasova, E. Sedlakova, Age Dependency on Some Physiological and Biochemical Parameters of Male Wistar Rats in Controlled Environment, 2012, pp. 1224–1233, <https://doi.org/10.1080/10934529.2012.672071>. <https://doi.org/10.1080/10934529.2012.672071>.
- H.B. Uysal, B. Dağlı, M. Yılmaz, F. Kahyaoglu, A. Gökçimen, I.K. Ömrürlü, B. Demirci, Biochemical and histological effects of thiamine pyrophosphate against



- acetaminophen-induced hepatotoxicity, *Basic Clin. Pharmacol. Toxicol.* 118 (2016) 70–76, <https://doi.org/10.1111/BCPT.12496>.
- [28] C.I. Nosiri, G. Oze, Liver enzyme levels of paracetamol induced hepatotoxic rats treated with aqueous leaf extract of *artocarpus altilis*, *Faseb. J.* 34 (2020) 1, <https://doi.org/10.1096/FASEBJ.2020.34.S1.09217>, 1.
- [29] A. Küçük, A. Gölgeli, R. Saraymen, N. Koc, Effects of age and anxiety on learning and memory, *Behav. Brain Res.* 195 (2008) 147–152, <https://doi.org/10.1016/j.bbr.2008.05.023>.
- [30] G. Üzümlü, K. Akgün-Dar, U. Aksu, The effects of atorvastatin on memory deficit and seizure susceptibility in pentylentetrazole-kindled rats, *Epilepsy Behav.* 19 (2010) 284–289, <https://doi.org/10.1016/j.yebeh.2010.07.024>.
- [31] S. Mastektomi, A. Diseksiyon, S. Seroma, G. Üzerine, K. İnsan, A. Membran, T. Zengin, P. Etkileri, M. Gömeç, The effects of cryopreserved human amniotic membrane and platelet-rich plasma on seroma development after mastectomy and axillary dissection in rats, *Düzce Tıp Fakültesi Derg.* 24 (2022) 78–84, <https://doi.org/10.18678/DTFD.1057914>.
- [32] J. Ozer, M. Ratner, M. Shaw, W. Bailey, S. Schomaker, The current state of serum biomarkers of hepatotoxicity, *Toxicology* 245 (2008) 194–205, <https://doi.org/10.1016/j.tox.2007.11.021>.
- [33] Z. Ge, C. Wang, J. Zhang, X. Li, J. Hu, Tempol protects against acetaminophen induced acute hepatotoxicity by inhibiting oxidative stress and apoptosis, *Front. Physiol.* 10 (2019) 660, <https://doi.org/10.3389/fphys.2019.00660/BIBTEX>.
- [34] M.T. Islam, C. Quispe, M.A. Islam, E.S. Ali, S. Saha, U.H. Asha, M. Mondal, A.F. A. Razi, U. Sunusi, R.M. Kamal, M. Kumar, J. Sharifi-Rad, Effects of nerol on paracetamol-induced liver damage in Wistar albino rats, *Biomed. Pharmacother.* 140 (2021), 111732, <https://doi.org/10.1016/j.biopha.2021.111732>.
- [35] P.K. Barman, R. Mukherjee, B.K. Prusty, S. Suklabaidya, S. Senapati, B. Ravindran, Chitohexaose protects against acetaminophen-induced hepatotoxicity in mice, *Cell Death Dis.* 75 (7) (2016), <https://doi.org/10.1038/cddis.2016.131>, 2016, e2224–e2224.
- [36] O. Farshad, P. Keshavarz, R. Heidari, M. Farahmandnejad, S. Azhdari, A. Jamshidzadeh, p>The potential neuroprotective role of citicoline in hepatic encephalopathy</p> &gt; J. Exp. Pharmacol. 12 (2020) 517–527, <https://doi.org/10.2147/JEP.S261986>.
- [37] M.M. Ommati, A. Jamshidzadeh, H. Niknahad, H. Mohammadi, S. Sabouri, R. Heidari, N. Abdoli, N-acetylcysteine treatment blunts liver failure-associated impairment of locomotor activity, *PharmaNutrition* 5 (2017) 141–147, <https://doi.org/10.1016/j.phanu.2017.10.003>.
- [38] M. Pylväs, U. Puistola, L. Laatio, S. Kauppila, P. Karihtala, Elevated serum 8-OHdG is associated with poor prognosis in epithelial ovarian cancer, *Anticancer Res.* 31 (2011) 1411–1415.
- [39] V. Valdíglesias, S. Giunta, M. Fenech, M. Neri, S. Bonassi,  $\gamma$ H2AX as a marker of DNA double strand breaks and genomic instability in human population studies, *Mutat. Res. Rev. Mutat. Res.* 753 (2013) 24–40, <https://doi.org/10.1016/j.mrrev.2013.02.001>.
- [40] R. Domitrović, H. Jakovac, V. Vasiljev Marchesi, S. Vladimir-Knežević, O. Cvijanović, Ž. Tadić, Ž. Romić, D. Rahelić, Differential hepatoprotective mechanisms of rutin and quercetin in CCl4-intoxicated BALB/cN mice, *Acta Pharmacol. Sin.* 33 (2012) 1260, <https://doi.org/10.1038/APS.2012.62>.
- [41] C.M. Park, Y.S. Song, Luteolin and luteolin-7-O-glucoside protect against acute liver injury through regulation of inflammatory mediators and antioxidative enzymes in GalN/LPS-induced hepatitic ICR mice, *Nutr. Res. Pract.* 13 (2019) 473, <https://doi.org/10.4162/NRP.2019.13.6.473>.
- [42] S. Yue, N. Xue, H. Li, B. Huang, Z. Chen, X. Wang, Hepatoprotective effect of apigenin against liver injury via the non-canonical NF- $\kappa$ B pathway in vivo and in vitro, *Inflammation* 43 (2020) 1634–1648, <https://doi.org/10.1007/S10753-020-01238-5>.
- [43] M.A.A. Ela, A.M. El-Lakany, M.S. Abdel-Kader, S.I. Alqasoumi, S.M. Shams-El-Din, H.M. Hammada, New quinic acid derivatives from hepatoprotective *Inula crithmoides* root extract, *Helv. Chim. Acta* 95 (2012) 61–66, <https://doi.org/10.1002/HLCA.201100282>.
- [44] P.H. Pan, S.Y. Lin, Y.Y. Wang, W.Y. Chen, Y.H. Chuang, C.C. Wu, C.J. Chen, Protective effects of rutin on liver injury induced by biliary obstruction in rats, *Free Radic. Biol. Med.* 73 (2014) 106–116, <https://doi.org/10.1016/j.freeradbiomed.2014.05.001>.
- [45] R.H. McAllister-Williams, D. Bertrand, H. Rollema, R.S. Hurst, L.P. Spear, T. C. Kirkham, T. Steckler, D. Capdevielle, J.-P. Boulenger, D. Capdevielle, J.-P. Boulenger, D. Capdevielle, J.-P. Boulenger, C. Höschl, M. Cadore, B.J. Harrison, C. Pantelis, A. Riley, S. Kohut, A. Hofer, B.J. Harrison, C. Pantelis, S.R. Pandi-Perumal, D. Warren Spence, S. Freedman Harris, M.J. Thorpy, M. Kramer, I. Stolerman, H.D. Brown, M. Ragozzino, K.A. Miczek, A. Jackson, S.O. Ögren, O. Stiedl, P.R. Pentel, M. LeSage, V.L. Harvey, T. Dickenson, C.A. Franco, M. N. Potenza, G. Winger, M.-C. Ko, J.H. Woods, M.I. Palmatier, R.A. Bevins, S. G. Anagnostaras, J.R. Sage, S.A. Carmack, J. Prickaerts, J. Prickaerts, J. Prickaerts, W.H. Meck, C.V. Buhushi, C.U. Correll, I. Stolerman, M. Shoaib, T. Robbins, D. Hoyer, T. Steckler, L.P. Spear, L. Tremolizzo, G. Sala, C. Ferrarese, S. Miyamoto, T. Steckler, D.S. Tait, V.J. Brown, R.A. Depue, T.L. White, C.A. Erickson, D. J. Posey, K. Blankenship, K.A. Stigler, C.J. McDougale, C.A. Erickson, D.J. Posey, K. Blankenship, K.A. Stigler, C.J. McDougale, I. Stolerman, J.-M. Scherrmann, S. Stevens Negus, D.E. Selley, L.J. Sim-Selley, C. Hiemke, M. Lader, S. Crabbe, P. Baumann, K. Wolff, C. Balthes, T. Mueggler, M. Rudin, A.J. Budney, R.L. Balster, S. Walsh, R.L. Balster, S. Walsh, R.L. Balster, S. Walsh, A. Bari, J. Mosbacher, P. Willner, K.A. Miczek, T. Robbins, W. Fleischhacker, E. Sibille, N. Edgar, S. M. Höfler, J.F. Cryan, M. Le Moal, M. Leyton, S. Tomlinson, G. Baker, B. Le Foll, N. Max Mirza, T. Schneider, J. Prickaerts, J. Prickaerts, R.L. Balster, S. Walsh, Y. Chudasama, T. Steckler, T. Steckler, D. Hoyer, S. Floresco, C.A. Franco, M. Potenza, F. Benedetti, P. Riederer, S. Hoyer, L. Tremolizzo, G. Sala, C. Ferrarese, L. Tremolizzo, G. Sala, C. Ferrarese, L. Tremolizzo, G. Sala, C. Ferrarese, A. Christopoulos, G.D. Stewart, P.M. Sexton, C. Hiemke, M. Lader, S. Leucht, M. Slištejn, L.P. Spear, S.G. Siris, S. Jones, P. Verheer, P. Svenningsson, P. André, S.R. Pandi-Perumal, M. Kramer, M.J. Thorpy, S.F. Harris, D.W. Spence, J. Atack, H. Lavreysen, S.C. Fowler, H. de Wit, B. Hahn, S.C. Fowler, H. Cassaday, P. Willner, D.R. Christensen, W.K. Bickel, M. Minzenberg, D. Baldwin, C.N. Epperson, C. N. Epperson, L. Scahill, I.T. Uzbay, B. Bizarro, B. Ellenbroek, L.P. Spear, P. D. McGorry, A.R. Yung, M.A. Geyer, J. Mosbacher, M. Lader, A. Roberts, C. Morgan, V. Curran, C.A. Franco, M. Potenza, C. Morgan, V. Curran, T. Steckler, H. de Wit, J.B. Becker, M. Cain, M.T. Bardo, T. Steckler, T. Robbins, T. Duka, S. Hutton, C.N. Epperson, C. Morgan, V. Curran, G. Winger, M.-C. Ko, J.H. Woods, P. Verheer, P. Svenningsson, P. André, M. Cammarota, L.R. Bevilacqua, I. Izquierdo, H. Manji, J. Quiroz, P.E. André, P. Verhaert, P. Svenningsson, J. Suzuki, T. Passie, P.E. Huertas, J. Halpern, E. Sibille, N. Edgar, G. Yararbas, S. Pogun, G. Hernandez, P. Shizgal, I. Hindmarch, I. Hindmarch, G.C. Kincheski, L. J. Bertoglio, A. Padua Carobrez, R.H. McAllister-Williams, W. Cahn, H.B.M. Boos, H.D. Postma, G. Fischer, A. Unger, M.J. Bubar, K.A. Cunningham, K. A. Cunningham, M.J. Bubar, M.-L. Wadenberg, J. Prickaerts, M.N. Branch, J. M. Witkin, J.E. Barrett, I. Izquierdo, L.R.M. Bevilacqua, M. Cammarota, Passive avoidance, *Encycl. Psychopharmacol.* (2010) 960–967, [https://doi.org/10.1007/978-3-540-68706-1\\_160](https://doi.org/10.1007/978-3-540-68706-1_160).
- [46] M. Méndez, M. Méndez-López, L. López, M.Á. Aller, J. Arias, J.L. Arias, Associative learning deficit in two experimental models of hepatic encephalopathy, *Behav. Brain Res.* 198 (2009) 346–351, <https://doi.org/10.1016/j.bbr.2008.11.015>.
- [47] S. Hajipour, A. Sarkaki, M. Dianat, M. Rashno, L.S. Khorsandi, Y. Farbood, The effects of thymoquinone on memory impairment and inflammation in rats with hepatic encephalopathy induced by thioacetamide, *Metab. Brain Dis.* 36 (2021) 991–1002, <https://doi.org/10.1007/S11011-021-00688-6>.
- [48] S.F. Nabavi, S. Tejada, W.N. Setzer, O. Gortzi, A. Surenda, N. Braidia, M. Daglia, A. Manayi, S.M. Nabavi, Chlorogenic acid and mental diseases: from chemistry to medicine, *Curr. Neuropharmacol.* 15 (2017) 471, <https://doi.org/10.2174/1570159X14666160325120625>.
- [49] B. Salehi, A. Venditti, M. Sharifi-Rad, D. Kregiel, J. Sharifi-Rad, A. Durazzo, M. Lucarini, A. Santini, E.B. Souto, E. Novellino, H. Antolák, E. Azzini, W.N. Setzer, N. Martins, The therapeutic potential of apigenin, *Int. J. Mol. Sci.* 20 (2019) 1305, <https://doi.org/10.3390/IJMS20061305>.