

## ← Journal information



### REVISTA MEXICANA DE CIENCIAS PECUARIAS

Publisher name: INIFAP-CENID PARASITOLOGIA VETERINARIA

#### Journal Impact Factor™

0.7

2022

1

Five Year

JCR Category	Category Rank	Category Quartile
AGRICULTURE, DAIRY & ANIMAL SCIENCE <i>in SCIE edition</i>	49/62	Q4

Source: Journal Citation Reports 2022. [Learn more](#)

#### Journal Citation Indicator™

0.18

2022

0.21

2021

JCI Category	Category Rank	Category Quartile
AGRICULTURE, DAIRY & ANIMAL SCIENCE <i>in SCIE edition</i>	68/79	Q4

The Journal Citation Indicator is a measure of the average Category Normalized Citation Impact (CNCI) of citable items (articles and reviews) published by a journal over a recent three year period. It is used to help you evaluate journals based on other metrics besides the Journal Impact Factor (JIF).

[Learn more](#)

# Master Journal List

Search Journals

Match Manuscript

Downloads

Help C

NEW

The power of the Web of Science™ on your mobile device, wherever inspiration strikes.

Dismiss

Learn More

### Already have a manuscript?

Use our Manuscript Matcher to find the best relevant journals!

Find a Match

## Refine Your Search Results

Rev Mex Cienc Pecu

Search

Sort By: Relevancy

### Filters

Clear All

Web of Science Coverage

Open Access

Category

Country / Region

Language

Frequency

Journal Citation Reports

## Search Results

Found 1,619 results (Page 1)

Share These Results

## Exact Match Found

### REVISTA MEXICANA DE CIENCIAS PECUARIAS

OPEN ACCESS

**Publisher:** INIFAP-CENID PARASITOLOGIA VETERINARIA , CARRETERA FEDERAL CUERNAVACA-CUAUTIA NO 8534, COL PROGRESO, JIUTEPEC C P, MEXICO, 06300 D F

**ISSN / eISSN:** 2007-1124 / 2448-6698

*Web of Science Core*

Collection:

Additional *Web of Science*

Indexes:

**Science Citation Index Expanded**

**Essential Science Indicators**


Share This Journal

View profile page


\* Requires free login.

## Other Possible Matches





## Effect of hesperidin supplementation on blood profile, antioxidant capacity, intestinal histomorphology and fecal microbial counts in Japanese quails



Abdullah Özbilgin <sup>a\*</sup>

Mahmut Niyazi Moğulkoç <sup>b</sup>

Füsun Erhan Bayçumendur <sup>c</sup>

Nazlı Ercan <sup>d</sup>

<sup>a</sup> Sivas Cumhuriyet University. Veterinary Faculty. Department of Animal Nutrition and Nutritional Disorders, Sivas, Turkey.

<sup>b</sup> Sivas Cumhuriyet University. Veterinary Faculty. Department of Veterinary Microbiology, Sivas, Turkey.

<sup>c</sup> Sivas Cumhuriyet University. Veterinary Faculty. Department of Veterinary Histology and Embriology, Sivas, Turkey.

<sup>d</sup> Sivas Cumhuriyet University. Veterinary Faculty. Department of Veterinary Biochemistry, Sivas, Turkey.

\*Corresponding author: [abdullahozbilgin@gmail.com](mailto:abdullahozbilgin@gmail.com)

### Abstract:

This study was conducted to determine the effects of hesperidin, a flavonoid added to quail diets, on blood serum, enzymes in tissues, intestinal histomorphology and fecal microflora. In the study, first treatment [(control) (0g hesperidin/kg feed)], second treatment [(HES1) (1 g hesperidin/kg feed)], third treatment [(HES2) (2 g hesperidin/kg feed)] was added to with the basal diet through 35 d. The study was carried out with 3 main groups, 20 quails with 5 sub-repeats in each group and a total of 300 quails. At the end of the study, blood, liver and thigh muscle tissue and fecal samples were taken. Alanine transaminase (ALT) and lactate dehydrogenase (LDH) decreased in the HES1 group but increased in the HES2 group compared to the control group ( $P<0.05$ ). Aspartate transaminase (AST) increased in the HES1 group compared to the control group and

decreased in the HES2 group ( $P<0.05$ ). Amylase, on the other hand, showed a regular increase in HES1 and HES2 groups to which hesperidin was added to the control group in hesperidin added groups ( $P<0.05$ ). The tissue antioxidant GSH, CAT and SOD enzyme parameters showed a significant increase in the hesperidin added groups compared to the control group, and this increase was found to be significant compared to the control group ( $P<0.05$ ). In intestinal histomorphology, in hesperidin treatment groups increased the height of villus in the cecum tissue; in colon tissue, it was determined that hesperidin added groups increased villus height but decreased crypt depth ( $P<0.05$ ). Consequently, diets hesperidin with treatments positively is thought to affect the lipid, thigh, liver and serum antioxidant enzyme levels, intestinal histomorphology and fecal microflora in quail.

**Keywords:** Blood, Feces, Flavonoid, Lipid, Tissue.

Received: 25/07/2022

Accepted: 08/03/2023

## Introduction

Japanese quail (*Coturnix coturnix Japonica*) has recently received more attention in the poultry industry due to increased meat and egg yield, especially in European and Latin American countries. Moreover, quail has become an important model animal for research due to its short life cycle and great resistance to many poultry diseases<sup>(1,2)</sup>. In quail feeding, alternative compounds are used today. Citrus have an additional advantage compared other sources due to the presence of bioactive compounds (flavonoids), used as functional components for providing health benefits. Bioflavonoids such as hesperidin and naringenin are abundant as an inexpensive by-product of citrus cultivation<sup>(3)</sup>. Flavonoids are secondary metabolites of plant origin called antioxidant heterocyclic organic compounds divided into 14 different subgroups according to the chemical structure and positions of the components on rings A, B and C<sup>(4)</sup>. Hesperidin (5, 7, 3'-trihydroxy-4'-methoxy-flavanone 7-rhamno glucoside), one of the primary flavonoids found in citrus fruit<sup>(5)</sup>, was formed from hesperidin and rutinose<sup>(6,7)</sup>, and have many biological properties, including antimicrobial, antioxidant and vascular activities<sup>(8)</sup>. These compounds prevent or delay the oxidation of structures such as proteins, lipids, carbohydrates. Flavonoids can be conjugated with glucuronic acid, and O-methylation or sulfate ester formation may occur to facilitate. This type of biotransformation occurs in the lower parts of the gastrointestinal tract. Some of the flavonoids that are not absorbed in the small intestine and other compounds are secreted by bile. They also contribute to the degradation process in the colon, in which microorganisms disrupt the ring

structures<sup>(9)</sup>. In general, data on the intestinal absorption of hesperidin are insufficient, and its fate in the intestine is still unclear<sup>(10)</sup>.

In recent studies, it has been reported that when hesperidin is added to quail rations, it increases meat quality at the end of fattening, positively affects fatty acids in meat, and egg quality parameters in layer quails<sup>(11,12)</sup>. Other studies reported that it promotes the activity of cellular antioxidant enzymes such as Superoxide Dismutase (SOD), Hemeoxygenase-1 (HO-1) and catalase (CAT)<sup>(13-17)</sup>.

In this study, it was hypothesized that the addition of hesperidin to the quail diet would have positive effects on blood parameters, antioxidant concentration in tissues, intestinal histomorphology and fecal microflora.

## Material and methods

### Chemicals

Hesperidin (molecular formula: C<sub>28</sub>H<sub>34</sub>O<sub>15</sub>, cas no: 520-26-13, purity 91%, Chem-Impex International Company, USA) was purchased commercially in powder form.

### Animals and dietary treatments

This study was carried out with the Ethics Committee Approval number 327/2022 of Sivas Cumhuriyet University Animal Experiments Local Ethics Committee. Japanese quails (300 quails, weighing 40-45 g and 1-2 wk old) were obtained from breeders in Sivas (39°42'34.8"N 37°01'13.0"E). The animals were kept in metal cages (Çimuka, Türkiye) (height: width: depth) (20\*45\*90 cm) with light for 21 h and darkness for 3 h at room temperature (25 ± 2 °C) for 35 d. The study was carried out with three main groups, 20 quails with 5 sub-repeats in each group and a total of 300 quails. The first treatment (control) (0 g hesperidin/kg feed), second treatment (HES1) (1 g hesperidin/kg feed), third treatment (HES2) (2 g hesperidin/kg feed) was added to with the basal diet through 35 d.

The diets used in the study were formulated according to the recommendations of NRC<sup>(18)</sup>. (Table 1). The granular feed and water were given *ad libitum*. Starting the study, an adaptation period for the environment and the feed was applied for one week. The dose of hesperidin was determined as is reported in previous study<sup>(3)</sup>. Quails were divided into three groups as control and study groups to study parameters such as blood parameters, antioxidant activity, intestinal histomorphology, and fecal microbial counts.

**Table 1:** Ingredients and nutrient composition of quail diet

Ingredients (%)	Diets <sup>1</sup>		
	C	HES1	HES2
Corn	44.29	44.29	44.29
Wheat grain	14.80	14.80	14.80
Soybean meal, % 48	37.65	37.65	37.65
Limestone <sup>2</sup>	0.81	0.71	0.61
Dicalcium phosphate	0.74	0.74	0.74
DL-methionine	0.50	0.50	0.50
L-threonine	0.50	0.50	0.50
Salt	0.42	0.42	0.42
L-lysine, hydrochloride	0.04	0.04	0.04
Vitamin-mineral mix <sup>3</sup>	0.25	0.25	0.25
Hesperidin <sup>4</sup>	0.00	0.10	0.20
Calculated values			
Dry matter, %	89.73	89.63	89.53
Crude protein, %	24.05	24.05	24.05
Ether extract, %	1.85	1.85	1.85
Crude ash, %	5.30	5.30	5.30
Crude cellulose, %	2.89	2.89	2.89
Metabolic energy, kcal/kg	2.900	2.900	2.900
Methionine+Cystine, %	1.27	1.27	1.27
Lysine, %	1.31	1.31	1.31
Threonine, %	1.37	1.37	1.37
Tryptophan, %	0.32	0.32	0.32
Calcium, %	0.61	0.57	0.53
Available phosphorus, %	0.31	0.31	0.31

<sup>1</sup> Diets: C – basal diet, HES1 – basal diet with 1 g/kg hesperidin, HES2 – basal diet with 2 g/kg hesperidin.

<sup>2</sup> hesperidin replaced limestone in the same amount in the groups with hesperidin addition.

<sup>3</sup> contained per kg: mg: retinol (vitamin A) 3, tocopherol (vitamin E) 30, menadione (vitamin K3) 5, thiamine (vitamin B1) 1, riboflavin (vitamin B2) 5, pyridoxin (vitamin B6) 3, nicotinic acid 30, pantothenic acid 10, folic acid 0.8, ascorbic acid (vitamin C) 10, choline chloride 450, Co 0.2, I 0.5, Se 0.3, Fe 25, Mn 120, Cu 10, Zn 100; µg: cholecalciferol (vitamin D3) 62.5, cobalamin (vitamin B12) 20, biotin 100; <sup>4</sup> obtained from Chem-Impex Int. company, molecule formula (C28H34O15), cas no (520-26-13), purity grade 91% (Chem-Impex, Wood Dale, IL, USA).

## **Slaughter procedures**

At the end of the study (35 d) (n=8\*3 groups total 24 animals), quails were not fed for 6 h and were slaughtered in a commercial slaughterhouse under hygienic conditions. The blood of slaughtered quails was taken into blood collection tubes and centrifuged at 3,000 rpm for 10 min. The serum was transferred to 2 ml of microcentrifuge tubes (Eppendorf, Germany) and kept in a freezer at -80 °C until the analysis were performed. The carcasses were placed in plastic bags one by one after the internal organs were evacuated and kept at +4°C for 24 h. The blood serum, the thigh (*Musculus gastrocnemius*) and the liver tissues were kept in a freezer at -80 °C until the analysis were performed.

## **Blood serum parameters**

Tchol (Total cholesterol), BUN (Blood Urea Nitrogen), ALT (Alanine amino Transferase), AST (Aspartate amino Transferase), GGT (Gamma Glutamyl Transferase), ALP (Alkaline Phosphatase), TP (Total Protein), TG (Triglyceride), CK (Creatin Kinase), LDH (Lactate Dehydrogenase), Ca (Calcium), Mg (Magnesium) P (Phosphorus), Urea, Kreatin, Albumin biochemical values were determined in serum samples using an auto-analyzer device (Mindray BS200, China).

## **Tissue parameters**

Liver, and thigh tissues were homogenized. Subsequently, GSH levels were determined using the ELABSCIENCE (E-BC-K030-M); SOD levels were detected using the ELABSCIENCE (E-BC-K022-M) CAT levels were determined using the ELABSCIENCE (E-BC-K031-M) MDA (Malondialdehyde) was measured using the ELABSCIENCE (E-BC-K298-M) LPO levels were detected using the ELABSCIENCE (E-BC-K176-M) corresponding to the absorbances of the serum and tissue samples calculated.

## **Intestinal histomorphology**

Ileum, cecum and colon samples were taken into tissue containers for histological preparation in a 10% buffered formula and washed in tap water for 48 h; 5 µm thick sections were taken from the tissues, followed by the histological tissue follow-up method that was applied routinely, were blocked in the paraffin wax. Hematoxylin - eosin staining

was performed on sections to determine the overall histological structures and perform histometric measurements<sup>(19)</sup>. The stained preparations were examined under a research microscope (Zeiss Primo Star, Germany) and their photos were taken. Villus height, villus width and crypt depth of the 10 pieces obtained from different parts of three sections belonging to each animal were measured using the ImageJ software. The villus height was measured at the vertical distance from the villus peaks to the starting point of the crypts, while the villus widths were obtained from measurements taken at the medium height of the villus. The depth of the crypt was calculated as the vertical distance from the villus-crypt junction to the lower boundary of the crypt<sup>(20)</sup>.

### Fecal microbial counts

One gram of fecal content from each quail was aseptically collected and homogenized with 9 mL of 0.1% peptone water. Serial 10-fold dilutions were made in sterile peptone water from  $10^{-1}$  to  $10^{-6}$  and 0.1 mL from last three dilutions were plated in duplicate onto respective selective medias.

*Escherichia coli* counts were performed on Tryptone Bile X-Glucuronide (TBX) agar and plates were incubated for 24 h at 37 °C. *Enterococci* were cultured on Slanetz Bartley agar (SB, Oxoid CM377, England) and enumerated after 24-48 h of incubation at 37 °C. *Enterobacteriaceae* and coliforms were grown on violet red bile glucose agar (VRBG, Oxoid CM485, England) and violet red bile agar (VRB, Oxoid CM107, England) respectively, using the pour plate technique and enumerated after 24-48 h of incubation at 37 °C. Tryptose Sulfite Cycloserine Agar (TSC Agar) Base (Merck 1.11972, Germany) was utilized for the *Clostridium* count. The plates were incubated for 24 h at 45 °C under anaerobic conditions, anaerobic indicator (Mitsubishi Gas Chemical, America) was included to monitor the atmospheric condition. Petri dishes (90 mm\*15 mm) (Firat Plastic, Türkiye) observed 30 to 300 colonies were counted using a colony counter<sup>(21)</sup>. The microbial counts were expressed as  $\log^{10}$  CFU per gram of fecal contents.

### Statistical analysis

The obtained data were evaluated using the SPSS 20.0 statistical package program. The data showed normal distribution in all parameters. One-way analysis of variance (ANOVA) was used and Bonferroni and Tamhane's T2 multiple comparison test was used for comparisons between groups ( $P < 0.05$ ).



## Results

### Blood serum parameters

Serum alanine transaminase (ALT) and lactate dehydrogenase (LDH) in the HES1 and the HES2 groups, were no different compared to the control group ( $P < 0.05$ ). Aspartate transaminase (AST) decreased in the HES2 group compared control group and HES1 ( $P < 0.05$ ). Amylase, on the other hand, showed an increase in HES2 compared to the control group ( $P < 0.05$ ) (Table 2). No significant differences were found between the experiment groups in the parameters of Tchol, TG, GGT, ALP, CK, BUN, Albumin, TP, Urea, Creatine, Glucose, Ca, Mg and P ( $P > 0.05$ ).

**Table 2:** The effect of hesperidin added to quail diets on blood serum biochemistry

	Control	HES1	HES2	
	Mean± SEM	Mean± SEM	Mean± SEM	P
Tchol, mg/dL	239.82±9.09	262.38±7.22	259.23±5.32	0.12
TG, mg/dL	265.35±24.77	248.40±25.59	247.43±26.77	0.86
ALT, U/L	5.50±0.65ab	4.25±0.48b	6.60±0.25a	0.01*
AST, U/L	237.50±6.89 <sup>a</sup>	243.00±5.51 <sup>a</sup>	194.60±9.66 <sup>b</sup>	0.001*
GGT, U/L	2.00±0.58	2.40±0.40	3.50±0.50	0.14
ALP, U/L	265.73±22.42	279.37±26.89	261.70±26.62	0.89
CK, U/L	2.422±197.57	2.614±211.07	2.650±242.93	0.78
LDH, U/L	711.93±36.69 <sup>ab</sup>	678.36±27.69 <sup>b</sup>	767.81±13.88 <sup>a</sup>	0.03*
Amylase, U/L	243.50±15.50 <sup>b</sup>	302.75±12.15 <sup>ab</sup>	355.50±18.68 <sup>a</sup>	0.01*
BUN, mg/dL	4.00±0.00	4.67±0.33	4.71±0.36	0.26
Albumin, g/dL	1.83±0.11	1.55±0.17	1.83±0.10	0.24
TP, g/dL	6.26±0.71	3.97±0.21	4.74±0.55	0.08
Creatin, mg/dL	0.18±0.02	0.16±0.01	0.19±0.04	0.82
Glucose, mg/dL	56.58±9.66	61.60±5.40	59.20±2.20	0.93
Ca, mg/dL	10.52±0.20	8.87±0.76	9.99±0.10	0.16
Mg, mg/dL	7.58±0.64	6.18±0.50	7.56±0.24	0.09

Tchol= total cholesterol, BUN= blood urea nitrogen, ALT= alanine amino transferase, AST= aspartate amino transferase, GGT= gamma glutamyl transferase, ALP= alkaline phosphatase, TP= total protein, TG= triglyceride, CK= creatin kinase, LDH= lactate dehydrogenase, P= phosphorus.

\*There is a statistically significant difference between the experimental groups ( $P < 0.05$ )

## Tissue parameters

GSH level increased in thigh, liver and serum tissue in HES1 group compared to control group ( $P<0.05$ ). In thigh tissue, it decreased in the HES2 group compared to the control group. LPO level increased in thigh and serum tissue in HES1 group compared to control group. In thigh tissue, it decreased in the HES2 group compared to the control group. and increased in HES2 groups in serum. In liver tissue, it decreased in HES1 and HES2 groups compared to the control group ( $P<0.05$ ). The CAT level in the thigh tissue was decreased in the hesperidin groups compared to the control group ( $P<0.05$ ). It increased in liver tissue ( $P>0.05$ ). In serum tissue, it decreased in HES1 and increased in HES2 ( $P<0.05$ ). MDA level decreased in thigh, liver and serum in HES1 and HES2 groups compared to control group ( $P<0.05$ ). On the other hand, while SOD level decreased in hesperidin groups in thigh tissue compared to the control group ( $P<0.05$ ); increased in HES1 and HES2 groups in liver tissue ( $P<0.05$ ). In the serum tissue, it decreased in the HES1 group compared to the control group, but increased in the HES2 group ( $P>0.05$ ) (Table 3).

**Table 3:** The effect of hesperidin added to the diet on oxidant parameters in thigh, liver and blood

		Control	HES1	HES2	
		Mean± SEM	Mean± SEM	Mean± SEM	P
GSH, $\mu\text{mol/L}$	Thigh	10.79±0.49	12.61±0.16	10.04±0.75	0.06
	Liver	6.33±1.01 <sup>c</sup>	12.77±0.65 <sup>b</sup>	19.62±0.65 <sup>a</sup>	0.001*
	Serum	51.68±1.34 <sup>b</sup>	75.16±1.24 <sup>a</sup>	70.88±0.42 <sup>a</sup>	0.01*
SOD, U/ml	Thigh	1.03±0.04 <sup>a</sup>	0.81±0.04 <sup>b</sup>	0.85±0.07 <sup>b</sup>	0.02*
	Liver	1.09±0.02	1.11±0.03	1.16±0.01	0.14
	Serum	0.37±0.12	0.32±0.13	0.42±0.11	0.84
CAT, U/ml	Thigh	211.62±0.72 <sup>a</sup>	101.55±1.16 <sup>b</sup>	61.56±0.91 <sup>c</sup>	0.001*
	Liver	76.13±1.31 <sup>b</sup>	88.40±4.18 <sup>ab</sup>	96.69±3.43 <sup>a</sup>	0.01*
	Serum	54.30±1.06 <sup>ab</sup>	51.33±1.25 <sup>b</sup>	61.65±1.03 <sup>a</sup>	0.02*
MDA, $\mu\text{mol/L}$	Thigh	758.53±42.62 <sup>a</sup>	642.30±43.17 <sup>ab</sup>	379.71±40.09 <sup>b</sup>	0.02*
	Liver	1.091.16±40.52 <sup>a</sup>	318.98±39.98 <sup>b</sup>	308.31±31.66 <sup>c</sup>	0.001*
	Serum	777.69±36.18 <sup>a</sup>	438.24±35.80 <sup>b</sup>	298.32±38.67 <sup>b</sup>	0.01*
LPO, $\mu\text{mol/L}$	Thigh	278.79±1.46 <sup>a</sup>	285.13±1.15 <sup>a</sup>	267.28±2.34 <sup>b</sup>	0.03*
	Liver	257.09±1.39 <sup>a</sup>	241.16±0.78 <sup>b</sup>	249.30±1.29 <sup>a</sup>	0.01*
	Serum	241.56±1.56 <sup>b</sup>	279.88±1.42 <sup>a</sup>	284.71±1.52 <sup>a</sup>	0.001*

GSH= reduced glutathione, SOD= superoxide dismutase, CAT= catalase, MDA= malondialdehyde, LPO= lipid peroxide.

\*There is a statistically significant difference between the experimental groups ( $P<0.05$ ).

## Intestinal histomorphology

In terms of histomorphology in the intestine, in ileum tissue, villus height increased in HES1 and HES2 groups compared to the control group ( $P<0.05$ ) (Table 4). villus height

increased in HES1 and HES2 groups compared to the control group in the caecum and colon tissue ( $P<0.05$ ). However, crypt depth in colon tissue decreased in HES1 and HES2 groups compared to control group ( $P<0.05$ ) (Figure 1).

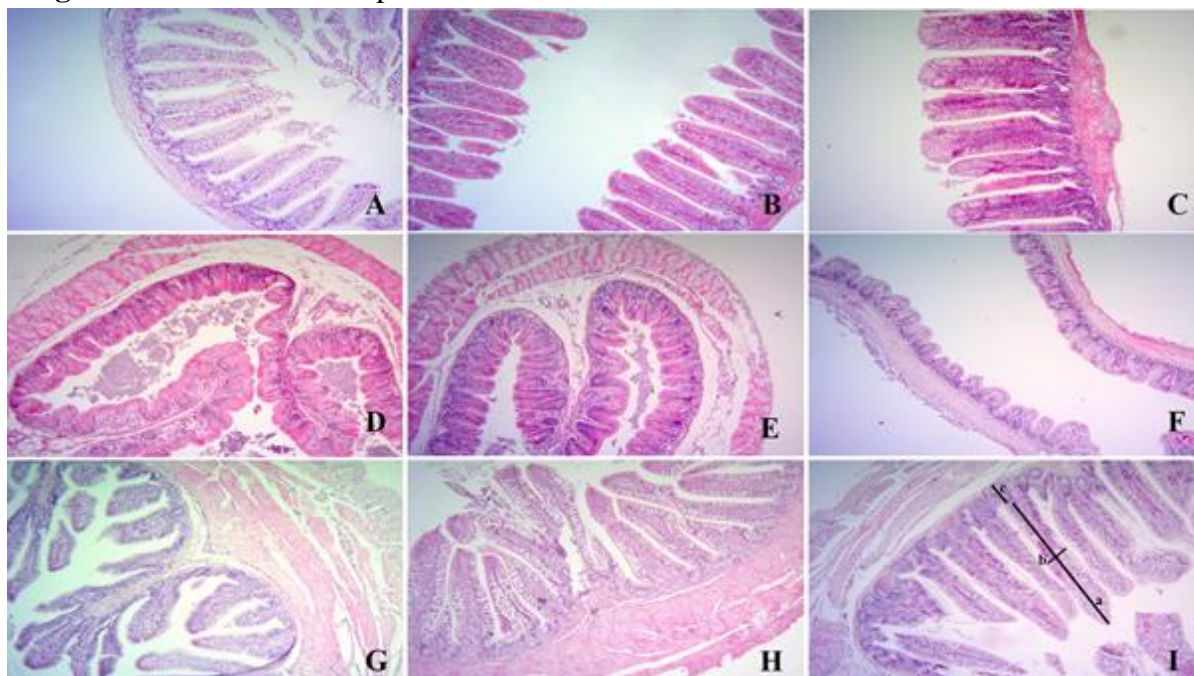
**Table 4:** The effect of hesperidin added to the diet on villus and crypt depth in the ileum, caecum and colon

		<b>Control</b>	<b>HES1</b>	<b>HES2</b>	
		<b>Mean±SEM</b>	<b>Mean±SEM</b>	<b>Mean± SEM</b>	<b>P</b>
Ileum	VH	222.42±13.53	234.53±21.69	264.24±22.43	0.33
	VW	67.21±1.97	64.70±5.47	67.10±2.54	0.86
	CD	30.50±1.24	31.71±1.82	35.02±3.55	0.41
Caecum	VH	71.40±3.79 <sup>b</sup>	85.56±4.24 <sup>a</sup>	79.86±1.28 <sup>ab</sup>	0.03*
	VW	41.33±2.47	42.76±1.28	47.81±1.55	0.06
	CD	44.45±3.45	38.15±1.78	41.80±1.58	0.22
Colon	VH	226.38±18.2 <sup>b</sup>	298.58±22.10 <sup>ab</sup>	312.50±28.75 <sup>a</sup>	0.04*
	VW	60.88±2.01 <sup>b</sup>	73.70±3.84 <sup>a</sup>	62.54±3.13 <sup>ab</sup>	0.02*
	CD	53.47±4.65 <sup>a</sup>	40.24±2.89 <sup>b</sup>	42.62±2.39 <sup>ab</sup>	0.04*

VH= villus height, VW= villus width, CD= crypt depth.

\*There is a statistically significant difference between the experimental groups ( $P<0.05$ ).

**Figure 1:** The effect of hesperidin addition to diet on ileum caecum and colon tissues



Control group: ileum (A), caecum (D), colon (G), HES1 group: ileum (B), caecum (E), colon (H), HES2 group: ileum (C), caecum (F), colon (I) tissue. a: villus height, b: villus width, c: crypt depth. Hematoxylin-eosin staining X10.

## Fecal microbial counts

In terms of fecal microflora, *Clostridium* spp. number decreased in HES1 and HES2 groups compared to the control group ( $P<0.05$ ) (Table 5). However, there is no significant difference between the experiment groups in terms of *Escherichia coli*, *Enterococcus* spp., *Coliform* spp. and *Enterobacteriaceae* counts ( $P>0.05$ ).

**Table 5:** The effect of dietary hesperidin on bacterial concentration (gram/Log<sup>10</sup>) in fecal samples

	<b>Control</b>	<b>HES1</b>	<b>HES2</b>	
	<b>Mean± SEM</b>	<b>Mean± SEM</b>	<b>Mean± SEM</b>	<b>p</b>
<i>Escherichia coli</i>	6.51±0.30	6.55±0.27	6.11±0.43	0.61
<i>Enterococcus</i> spp.	6.37±0.34	6.05±0.28	6.77±0.25	0.27
<i>Coliform</i> spp.	6.27±0.36	6.09±0.25	5.44±0.18	0.20
<i>Enterobacteriaceae</i>	6.43±0.24	5.65±0.26	6.65±0.24	0.88
<i>Clostridium</i> spp.	6.55±0.07 <sup>a</sup>	5.93±0.27 <sup>a</sup>	5.26±0.11 <sup>b</sup>	0.01*

\*There is a statistically significant difference between the experimental groups ( $P<0.05$ ).

## Discussion

### Serum biochemistry

Dietary antioxidant supplements can improve the physiology and yield characteristics of animals by changing metabolic processes<sup>(17)</sup>. The current study aimed to investigate the effects of hesperidin on biochemical parameters and antioxidant indices in quails. Citrus flavonoids, such as hesperidin and naringin, obtained from citrus fruits and fruit juices have been associated with lower cholesterol and triglyceride levels in animals in the previous studies<sup>(22,23)</sup>. The hypocholesterolemic effect of hesperidin has been reported to be mediated by a decrease in the activity of HMG-Co A reductase<sup>(24)</sup>. In the current study, both triglyceride and cholesterol levels no decreased in the groups with hesperidin ( $P>0.05$ ).

ALT and AST and LDH are enzymes related to liver health, function and it is desirable that they be low. In rats given 5g/kg of flavonoid daily, it was reported that ALT and AST concentrations decreased compared to the control group<sup>(25)</sup>. Abdel-Kareem and El-Sheikh<sup>(26)</sup> also reported 250, 500 and 1000 mg/kg, Galal *et al*<sup>(27)</sup> found that 100 and 150 mg/kg propolis significantly reduced AST and ALT activities in laying hens. In the

current study, AST enzyme levels decreased in the reason for the decrease in ALT, AST and LDH with different doses of hesperidin is unknown.

Antioxidant compounds taken from the diet, such as bioflavonoids, can provide some protection against the early stage of diabetes and the development of complications. It has been reported that hesperidin significantly reduces glucose in the blood<sup>(28)</sup>. However, unlike previous studies, the serum glucose concentration increased slightly in the current study ( $P>0.05$ ). To interpret the increase in glucose concentration, it is necessary to look at the plasma insulin concentration.

### **Tissue oxidant vs antioxidant enzymes**

The concentration of SOD enzymes in thigh samples was found to be low, but as high as expected in liver tissue. In general, this effect of hesperidin on the oxidation parameter indicates that it can terminate oxidation by adding hydrogen atoms to free radicals. Under physiological conditions, reactive oxygen species (ROS) production is regulated both endogenously and by antioxidant supplementation<sup>(29,30)</sup>. The main endogenous antioxidant enzymes are superoxide dismutase (SOD), catalase (CAT) and glutathione peroxidase (GPX)<sup>(31)</sup>. SOD converts hydrogen peroxide, which is one of the superoxide radicals, into oxygen and water under the action of CAT and/or GPX. While SOD and GPX are formed in many tissues<sup>(32)</sup>, CAT is highly present in liver, kidney tissues and red blood cells<sup>(33)</sup>. The membranes of immune cells are made of highly polyunsaturated fatty acids, making them highly sensitive to oxidative stress<sup>(34)</sup>. Therefore, they present high concentrations of antioxidant enzymes since membrane-related signaling and gene expression are critical for maintaining immune cell functionality<sup>(32)</sup>. In the current study, it is believed that the concentrations of thigh and serum tissues and liver and serum tissues in terms of GSH parameter and CAT parameter, respectively, increase in relation to the hesperidin supplementation. In another study, it has been reported that the concentration of hesperidin in animals was lower in terms of SOD activity in rats undergoing a fatigue test<sup>(35)</sup>. Lien *et al*<sup>(36)</sup> and Ting *et al*<sup>(37)</sup> reported that the concentration of superoxide dismutase (SOD) in the blood serum was high with the addition of hesperidin and naringin (0.5-4.0 g/kg) to broiler rations.

Previous studies reported that a significant decrease in MDA concentration were observed in broilers consuming rations with grape pulp (1.5, 3 and 6 %) in terms of MDA, which is one of the oxidant parameters, compared to those consuming a basal diet<sup>(38,39)</sup>. In another study, when broilers were fed a commercial essential oil mixture (0.05 % of the diet), a decrease in MDA was observed in the breast (22.4 %) and thigh (62.3 %) muscles when fed with a commercial essential oil mixture<sup>(40)</sup>. In addition, the inclusion of hesperidin (0.15 % or 0.3 %) to the rations of broilers has been reported to reduce the concentration of MDA in the breast muscle<sup>(41)</sup>. In the current study, as in the studies noted above, it is denser in the liver due to hesperidin, and the MDA value decreased in the

same way in thigh and serum. In addition, a decrease in LPO, which is an essential parameter in terms of tissue damage, is expected from the point of view of the current study due to the dose of hesperidin in thigh and liver tissue. The reason for this is that the body fat composition of adult quails is rich in unsaturated fatty acids, which is seen in studies conducted due to the increase in the dose of hesperidin in recent years<sup>(11,12)</sup>.

### **Intestinal histomorphology**

Hesperidin sulfates will be conjugated and absorbed in the duodenum and ileum after oral administration. Previous studies have shown a small amount of absorption of flavonoid glycosides in the small intestine<sup>(42)</sup>. The absence of glucuronide detection in intestinal tissue may be due to the restriction of tissue penetration of glucuronide<sup>(43)</sup>.

Recent studies have reported that flavonoids in a natural form (flavonoid-rich plants) or the extracts thereof had positive effects on immunomodulatory and intestine, including the increasing villus length in broilers and surface area of the small intestine<sup>(44-46)</sup>. Kamboh and Zhu<sup>(20)</sup> found that, among broilers consuming added rations of hesperidin, the length of the intestinal villus and the width of the villus (21<sup>st</sup> and 42<sup>nd</sup> d) increased, while the depth of the crypt (21 d in the duodenum and ileum, and 42 d in the duodenum) decreased. In the current study, the height and width of the villus in the ileum, cecum and colon also increased relatively. Flavonoid compounds that improve intestinal morphology differences measured in villus height and width have shown that these compounds can stimulate epithelial cell mitosis. That is because longer or thicker (or both) villus are associated with active mitosis, and it is believed that the villus continues long-term absorption without the need for regeneration and a reduced crypt depth. This is because the crypt is considered a villus factory, and that the large crypt presents rapid tissue transformation due to inflammation caused by pathogens, toxins, or both<sup>(47,48)</sup>. In addition, increased villus length/crypt depth ratios with genistein and hesperidin can be considered an improvement in the digestive system<sup>(49)</sup>. It is that similar results to previous studies will be obtained in the current study.

### **Fecal microbial counts**

In the current study, a lower concentration was determined in hesperidin groups in terms of the population of *Clostridium* spp. in a similar way to the previous studies. Today, plant extracts commercially used in livestock due to their performance-enhancing and antimicrobial effects are available in pure or mixed form. It is known that phenolic compounds and essential oils obtained from plants have antimicrobial effects<sup>(16,50)</sup>. The intestinal flora contained in the colon promotes the absorption of certain nutrients,

including polyphenols, from the diet and forms bioactive and absorbable molecules from dietary compounds<sup>(51)</sup>. Metabolites, consisting of both polyphenols and flora, can positively effect on health<sup>(52)</sup>. Additionally, numerous benefits of polyphenol metabolites derived by microflora on the host<sup>(53)</sup> have been reported.

Flavonoids have the property of low bioavailability and poor absorption. Therefore, they significantly affect intestinal health<sup>(54,55)</sup>. Phenolic compounds possess bactericidal<sup>(53)</sup> and bacteriostatic<sup>(54)</sup> properties. They minimize the adhesion of pathogenic bacteria (*E. coli*, *Clostridium* spp.) to the intestinal wall and prevent infections in the digestive tract. They also improve the use of nutrients and animals' performance<sup>(55-58)</sup>.

Zhang *et al*<sup>(59)</sup> have reported in their study that polyphenols added in piglet rations did not have a significant effect of feces *E. coli* and *Clostridia* spp. numbers on the 11<sup>th</sup> and 21<sup>st</sup> d. Kırkpınar *et al*<sup>(60)</sup> have noted a decrease in *Clostridium* spp. populations in the ileums of broilers fed with thyme oil, garlic oil and both substances compared to animals in other groups. Supplementation of cranberry extract (80 mg/kg feed), which is a source of phenolic acid, anthocyanin, flavonol and flavan-3-ol, to broiler rations has decreased *Enterococcus* spp. populations significantly in broilers on the 28<sup>th</sup> d of the study<sup>(61)</sup>.

## Conclusions and implications

As a result, hesperidin supplementation has positive effects in terms of blood parameters, antioxidant activity, intestinal histomorphology and fecal microflora.

## Acknowledgements and conflict of interest

All the authors worked in a coordinated way. The experiment was planned and conducted by AÖ. Antioxidant parameter analyzes by NE; intestinal histomorphology by FEB, microflora analysis by AÖ and MNM; The editing part and article writing was done by AÖ

## Literature cited:

1. Ikhlas B, Huda N, Noryati I. Chemical composition and physicochemical properties of meatballs prepared from mechanically deboned quail meat using various types of flour. *Int J Poult Sci* 2011;10:30–37.
2. Purohit AS, Reed C, Mohan A. Development and evaluation of quail breakfast sausage. *LWT* 2016;69:447–453.

3. Goliomytis M, Kartsonas N, Charismiadou MA, Symeon GK, Simitzis PE, Deligeorgis SG. The influence of naringin or hesperidin dietary supplementation on broiler meat quality and oxidative stability. *PLoS One* 2015;10(10):e0141652.
4. Cushnie TPT, Lamb AJ. Recent advances in understanding the antibacterial properties of flavonoids. *Int J Antimicrob Agents* 2011;38:99–107.
5. Cano A, Medina A, Bermej A. Bioactive compounds in different citrus varieties. Discrimination among cultivars. *J Food Compos Anal* 2008;21(5):377-381.
6. Cho J. Antioxidant and neuroprotective effects of hesperidin and its aglycone hesperetin. *Arch Pharm Res* 2006;29:699-706.
7. Kumar A, Lalitha S, Mishra J. Hesperidin potentiates the neuroprotective effects of diazepam and gabapentin against pentylenetetrazole-induced convulsions in mice: Possible behavioral, biochemical and mitochondrial alterations. *Indian J Pharmacol* 2014;46:309-315.
8. Martini ND, Katerere DRP, Eloff JN. Biological activity of five antibacterial flavonoids from *Combretum erythrophyllum* (Combretaceae). *J Ethnopharmacol* 2004;93:207–212.
9. Hollman PCH, Katan MB. Dietary flavonoids: intake, health effects and bioavailability. *Food Chem Toxicol* 1999;37:937-942.
10. Guo X, Li K, Guo A, Li E. Intestinal absorption and distribution of naringin, hesperidin, and their metabolites in mice. *J Funct Foods* 2020;74:104158.
11. Özbilgin A, Kara K, Gümüş R, Tekçe E. Fatty acid compositions and quality of egg and performance in laying quails fed diet with hesperidin. *Trop Anim Health Prod* 2021;53:518.
12. Özbilgin A, Kara K, Urcar Gelen S. Effect of hesperidin addition to quail diets on fattening performance and quality parameters, microbial load, lipid peroxidation and fatty acid profile of meat. *J Anim Feed Sci* 2021;30(4):367–378 .
13. Khedr NF. Protective effect of mirtazapine and hesperidin on cyclophosphamide-induced oxidative damage and infertility in rat ovaries. *Exp Biol Med* 2015;240(12): 1682–1689.
14. Roohbakhsh A, Parhiz H, Soltani F, Rezzee R, Iranshahi M. Molecular mechanisms behind the biological effects of hesperidin and hesperetin for the prevention of cancer and cardiovascular diseases. *Life Sci* 2015;1(124):64–74 .
15. Parhiz H, Roohbakhsh A, Soltani F, Rezaee R, Iranshahi M. Antioxidant and anti-inflammatory properties of the citrus flavonoids hesperidin and hesperetin: an updated review of their molecular mechanisms and experimental models. *Phytother Res* 2015;29(3):323–331.



16. Purba RAP, Yuangklang C, Paengkoum S, Paengkoum P. Milk fatty acid composition, rumen microbial population and animal performance in response to diets rich in linoleic acid supplemented with *Piper betle* leaves in Saanen goats. Anim Prod Sci 2020. <http://dx.doi.org/10.1071/AN20182>.
17. Purba RAP, Paengkoum S, Yuangklang C, Paengkoum P, Salem AZM, Liang JB. Mammary gene expressions and oxidative indicators in ruminal fluid, blood, milk, and mammary tissue of dairy goats fed a total mixed ration containing piper meal (*Piper betle* L.). Ital J Anim Sci 2022;21(1):129-141.
18. National Research Council (NRC). 1994. Nutrient requirements of poultry. 9th Edition, National Academy Press, Washington DC.
19. Bancroft JD, Gamble M. Theory and practice of histological techniques. 5th ed. Philadelphia PA. Elsevier Limited, 2002.
20. Kamboh AA, Zhu WY. Individual and combined effects of genistein and hesperidin on immunity and intestinal morphometry in lipopolysaccharide-challenged broiler chickens. Poult Sci 2014;93:9:2175–2183. <https://doi.org/10.3382/ps.2014-03971>.
21. Jin LZ, Ho YW, Abdullah N, Jalaludin S. Influence of dried *Bacillus subtilis* and lactobacilli cultures on intestinal microflora and performance in broilers. Asian-Australas J Anim Sci 1996;9:397-404.
22. Selvaraj P, Pugalendi KV. Efficacy of hesperidin on plasma, heart and liver tissue lipids in rats subjected to isoproterenol-induced cardiotoxicity. Exp Toxicol Pathol 2012;64(5):449-452.
23. Ohtsuki K, Abe A, Mitsuzumi H, Kondo M, Uemura K, Iwasaki Y, Kondo Y. Glucosyl hesperidin improves serum cholesterol composition and inhibits hypertrophy in vasculature. J Nutr Sci Vitaminol 2003;49(6):447-450.
24. Lee SJ, Yun YS, Lee IK, Ryoo IJ, Yun BS, Yoo ID. An antioxidant lignan and other constituents from the root bark of *Hibiscus syriacus*. Planta Med 1999;65:658–660.
25. Alghazeer R, Elgahmasi S, Elnfati AH, *et al.* Antioxidant activity and hepatoprotective potential of flavonoids from *Arbutus pavarii* against CCl<sub>4</sub> induced hepatic damage. Biotechnol J Int 2017;21(1):1–12.
26. Abdel-Kareem AA, El-Sheikh TM. Impact of supplementing diets with propolis on productive performance, egg quality traits and some haematological variables of laying hens. J Anim Physiol Anim Nutr (Berl) 2017;101:441–448.
27. Galal A, Abd El-Motaal AM, Ahmed AMH, Zaki TG. Productive performance and immune response of laying hens as affected by dietary propolis supplementation. Int J Poult Sci 2008;7:272-278.

28. Jung UJ, Lee MK, Jeong KS, Chol MS. The hypoglycemic effects of hesperidin and naringin are partly mediated by hepatic glucose regulating enzymes in C57 BL/KsJ-db/db Mice. *J Nutr* 2004;134:2499–2503.
29. Birben E, Sahiner UM, Sackesen C, Erzurum S, Kalayci O. Oxidative stress and antioxidant defense. *World Allergy Organ J* 2012;5:9–19.
30. Martemucci G, Costagliola C, Mariano M, D'andrea L, Napolitano P, D'Alessandro AG. Free radical properties, source and targets, antioxidant consumption and health. *Oxygen* 2022;2(2):48-78.
31. Pingitore A, Pace G, Lima P, Mastorci F, Quinones A, Iervasi G, Vassalle C. Exercise and oxidative stress: Potential effects of antioxidant dietary strategies in sports. *Nutr* 2015;31:916–922.
32. Griess B, Tom E, Domann F, Teoh-Fitzgerald M. Extracellular superoxide dismutase and its role in cancer. *Free Radic Biol Med* 2017;112:464–479.
33. Glorieux C, Calderon PB. Catalase, a remarkable enzyme: Targeting the oldest antioxidant enzyme to find a new cancer treatment approach. *Biol Chem* 2017;398:1095–1108.
34. Knight JA. Review: Free radicals, antioxidants, and the immune system. *Ann Clin Lab Sci* 2000;30:145–158.
35. Estruel-Amades S, Massot-Cladera PM, Garcia-Cerdà FJ, Pérez-Cano À, Franch M, Castell M, Camps-Bossacoma M. Protective effect of hesperidin on the oxidative stress induced by an exhausting exercise in intensively trained rats. *Nutrients* 2019;11(4):783.
36. Lien TF, Yeh HS, Su WT. Effect of adding extracted hesperetin, naringenin and pectin on egg cholesterol, serum traits and antioxidant activity in laying hens. *Arch Anim Nutr* 2008;62(1):33-43.
37. Ting S, Yeh HS, Lien TF. Effects of supplemental levels of hesperetin and naringenin on egg quality, serum traits and antioxidant activity of laying hens. *Anim Feed Sci Technol* 2011;163:59-66.
38. Brenes A, Viveros A, Goni I, Centeno C, Sayago-Ayerdy SG, Arija I, Saura-Calixto F. Effect of grape pomace concentrate and vitamin E on digestibility of polyphenols and antioxidant activity in chickens. *Poult Sci* 2008;87:307–316.
39. Goni I, Brenes A, Centeno C, Viveros A, Saura-Calixto F, Rebole A, Arija I, Estevez R. Effect of dietary grape pomace and vitamin E on growth performance, nutrient digestibility, and susceptibility to meat lipid oxidation in chickens. *Poult Sci* 2007;86:508–516.

40. Botsoglou NA, Christaki E, Florou-Paneri P, Giannenas I, Papageorgiou G, Spais AB. The effect of a mixture of herbal essential oils or  $\alpha$ -tocopheryl acetate on performance parameters and oxidation of body lipid in broilers. *S Afr J Anim Sci* 2004;34:52–61.
41. Simitzis PE, Symeon GK, Charismiadou MA, Ayountanti AG, Deligeorgis SG. The effects of dietary hesperidin supplementation on broiler performance and chicken meat characteristics. *Can J Anim Sci* 2011;91:275–282.
42. Escudero-Lopez B, Calani L, Fernandez-Pachon MS, Ortega A, Brighenti F, Crozier A, Del Rio D. Absorption, metabolism, and excretion of fermented orange juice (poly)phenols in rats. *Biofactors* 2014;40(3):327–335.
43. Joshi R, Kulkarni YA, Wairkar S. Pharmacokinetic, pharmacodynamic and formulations aspects of Naringenin: An update. *Life Sci* 2018;215:43–56. <https://doi.org/10.1016/j.lfs.2018.10.066>.
44. Hanieh H, Gerile C, Narabara K, Gu Z, Abe A, Kondo Y. *In vivo* immunomodulatory effects of dietary purple sweet potato after immunization in chicken. *Anim Sci J* 2010;81:116-121
45. Hassanpour H, Zamani MAK, Yazdani A, Cheraghchi BM. Evaluation of intestinal morphology and nitric oxide metabolites in broiler chickens supplemented by green tea. *Comp Clin Path* 2010;19:43-47.
46. Wallace J, Oleszek W, Franz C, Hahn I, Baser KH, Mathe A, Teichmann K. Dietary plant bioactives for poultry health and productivity. *Br Poult Sci* 2010;51:461-487.
47. Giannenas I, Tontis D, Tsalie E, Chronis EF, Doukas D, Kyriazakis I. Influence of dietary mushroom *Agaricus bisporus* on intestinal morphology and microflora composition in broiler chickens. *Res Vet Sci* 2010;89:78-84.
48. Awad WA, Ghareeb K, Bohm J. Evaluation of the chicory inulin efficacy on ameliorating the intestinal morphology and modulating the intestinal electrophysiological properties in broiler chickens. *J Anim Physiol Anim Nutr (Berl)* 2011;95:65-72.
49. Hu Z, Guo Y. Effects of dietary sodium butyrate supplementation on the intestinal morphological structure, absorptive function and gut flora in chickens. *Anim Feed Sci Technol* 2007;132:240–249.
50. Cross DE, McDevitt RM, Hillman K, Acamovic T. The effect of herbs and their associated essential oils on performance, dietary digestibility and gut microflora in chickens from 7 to 28 days of age. *Br Poult Sci* 2007;48:496-506.
51. Danneskiold-Samsøe NB, Dias de Freitas QBH, Santos R, Bicas JL, Cazarin CBB, Madsen L, *et al.* Interplay between food and gut microbiota in health and disease. *Food Res Int* 2019;115:23–31.

52. Anhê FF, Nachbar RT, Varin TV, Trottier J, Dudonné S, Le Barz M, *et al.* Treatment with camu camu (*Myrciaria dubia*) prevents obesity by altering the gut microbiota and increasing energy expenditure in diet-induced obese mice. *Gut* 2019;68:453–464.
53. Chávez-Carbajal A, Nirmalkar K, Pérez-Lizaur A, Hernández-Quiroz F, Ramírez-Del-Alto S, García-Mena J, Hernández-Guerrero C. Gut microbiota and predicted metabolic pathways in a sample of Mexican women affected by obesity and obesity plus metabolic syndrome. *Int J Mol Sci* 2019;20:438.
54. Etxeberria U, Fernández - Quintela A, Milagro FI, Aguirre L, Martínez JA, Portill MP. Impact of polyphenols and polyphenol-rich dietary sources on gut microbiota composition. *J Agric Food Chem* 2013;61:9517–9533.
55. Brenes A, Viveros A, Chamorro S, Arija I. Use of polyphenol-rich grape by-products in monogastric nutrition. A review. *Anim Feed Sci Technol* 2016;211:1–17.
56. Gordon NC, Png K, Wareham DW. Potent synergy and sustained bactericidal activity of vancomycin-colistin combination versus multidrug-resistant strains of *Acinetobacter baumannii*. *Antimicrob Agents Chemother* 2010;54:5316-5322.
57. Viveros A, Chamorro S, Pizarro M, Arija I, Centeno C, Brenes A. Effects of dietary polyphenol-rich grape products on intestinal microflora and gut morphology in broiler chicks. *Poult Sci* 2011;90:566–578.
58. Dueñas M, Muñoz - González I, Cueva C, Jiménez – Girón A, Sánchez - Patán F, Santos - Buelga C, Bartolomé B. A survey of modulation of gut microbiota by dietary polyphenols. *Biomed Res Int* 2015;2015:850902.
59. Zhang YS, Li Y, Wang Y, Sun SY, Qu XJ. Naringin, a natural dietary compound, prevents intestinal tumorigenesis in *apc* (min/+) mouse model. *J Cancer Res Clin Oncol* 2015;178(5):1-13. <http://dx.doi.org/10.1007/s00432-015-2097-9>.
60. Kırkpınar F, Ünlü KB, Özdemir G. Effects of oregano and garlic essential oils on performance, carcass, organ and blood characteristics and intestinal microflora of broilers. *Livest Sci* 2011;137:219-225.
61. Leusink G, Rempel H, Skura B, Berkyto M, White W, Yang Y, *et al.* Growth performance, meat quality, and gut microflora of broiler chickens fed with cranberry extract. *Poult Sci* 2010;89(7):1514–1523.