



# Hepatoprotective and neuroprotective effect of taxifolin on hepatic encephalopathy in rats

Ufuk Okkay<sup>1</sup> · Irmak Ferah Okkay<sup>2</sup> · Betül Cicek<sup>3</sup> · Ismail Cagri Aydin<sup>4</sup> · Mustafa Ozkaraca<sup>5</sup>

Received: 23 December 2021 / Accepted: 8 March 2022 / Published online: 17 March 2022  
© The Author(s), under exclusive licence to Springer Science+Business Media, LLC, part of Springer Nature 2022

## Abstract

This study was planned to assess the potential protective effects of taxifolin against thioacetamide-induced hepatic encephalopathy and subsequently to portray its behavioural results. The experimental model was induced with three doses of (200 mg/kg i.p.) thioacetamide and taxifolin (50 and 100 mg/kg, p.o.) was administered for fourteen days. Taxifolin effectively attenuated hepatic encephalopathy through decrease in AST, ALT, ALP and LDH concentrations and improvement of hyperammonemia, and increase in antioxidant capacity by decreasing MDA, ROS, and increasing CAT and GSH. In addition, the expressions of NF- $\kappa$ B, TNF- $\alpha$ , IL-1 $\beta$ , caspase-3 and Bax was down-regulated while IL-10 and Bcl-2 expressions were up-regulated with taxifolin treatment. The recovery was confirmed by downregulation of iNOS and 8-OHdG expressions in our immunohistochemical analysis. Taxifolin treatment reduced the disrupting role of thioacetamide as seen by corrected hyperammonemia as well as preservation of astrocyte and hepatocyte structure. Elevated plus maze and locomotor activity tests also proved that taxifolin might repeal the neurobehavioral disabilities. In conclusion, taxifolin has shown hepatoprotective and neuroprotective roles with antioxidant and anti-inflammatory effects, as well as suppressing the excessive release of ammonia, and it eventually reversed neurobehavioral impairments.

**Keywords** Thioacetamide · Taxifolin · Inflammation · Apoptosis · Oxidative stress · Hepatic encephalopathy

## Introduction

Hepatic encephalopathy (HE) is a critical neurologic dysfunction with neuropsychiatric abnormalities including cognitive deficits, sensory abnormalities, altered motor activity and spatial memory disfunction with character flaws (Liu et al. 2018). Many factors pertaining to severe hepatic dysfunctions, in particular cirrhosis, participate in the progression of the disease (Sun et al. 2020). Although

the pathogenesis of HE is multifactorial and still needs to be clarified, the common current theory is cumulative ammonia concentration and diverse neurotoxins in the brain due to damaged hepatic functions (Montes-Cortes et al. 2018). Hyperammonemia takes part in the pathogenesis of the disease as it causes neural injury and eventual cognitive and motor disorders as a result of its toxic effects on the central nervous system (Erceg et al. 2006). Moreover, as a powerful oxidant, ammonia implicates the production of reactive oxygen species (ROS) in astrocytes and induces oxidative stress, which acts in concert with neuroinflammation with exaggerated cytokine release through various mechanisms (Gow 2017; McMillin et al. 2014).

Thioacetamide (THA) is a sulphur-containing catalyst that causes hepatotoxicity and can induce liver fibrosis, activation of macrophages, and the secretion of several inflammatory cytokines (Butterworth 2011, Randolph et al. 2009). In the report of the International Society for Hepatic Encephalopathy and Nitrogen Metabolism (ISHEN), THA-related hepatotoxicity in rats is a well-defined experimental model of HE (Butterworth et al. 2009). In the current study,

✉ Ufuk Okkay  
ufukokkay@atauni.edu.tr

<sup>1</sup> Medical Pharmacology Department, Faculty of Medicine, Ataturk University, 25100 Erzurum, Turkey

<sup>2</sup> Pharmacology Department, Faculty of Pharmacy, Ataturk University, Erzurum, Turkey

<sup>3</sup> Physiology Department, Faculty of Medicine, Erzincan Binali Yildirim University, Erzincan, Turkey

<sup>4</sup> Pharmacology Department, Faculty of Pharmacy, Erzincan Binali Yildirim University, Erzincan, Turkey

<sup>5</sup> Pathology Department, Faculty of Veterinary Medicine, Sivas Cumhuriyet University, Sivas, Turkey

THA was utilized as a hepatotoxic-agent, considering the toxic and oxidizing effects of THA on the liver and the brain.

Taxifolin (dihydroquercetin, (2R,3R)-2-(3,4-dihydroxyphenyl)-3,5,7-trihydroxy-2,3-dihydrochromen-4-one) (TX) is a potent flavonoid found in many plants like French maritime pine bark and milk thistle. TX has been shown to have antioxidative, anti-inflammatory and anti-apoptotic effects. (Park et al. 2016; Sunil and Xu 2019; Topal et al. 2016; Wang et al. 2006). In recent years, hepatoprotective effects of TX have been reported in studies related to the liver injury and fibrosis (Yang et al. 2019; Zhan et al. 2021). In addition to its protective effects on the liver, beneficial effects of taxifolin in Alzheimer's disease, cerebral ischemia and various neurotoxicity models have also been reported (Gunesch et al. 2020; Inoue et al. 2019; Tanaka et al. 2019; Wang et al. 2006).

Keeping in mind the hepatoprotective and neuroprotective effects of TX, the current research was planned to evaluate the potential protective role of TX against THA-induced HE and subsequently portray its behavioural consequences.

## Materials and methods

### Chemical and reagents

TX (Cas Number # 480–18-2) and THA (Cas Number # 62–55-5) were obtained from SigmaAldrich-USA.

### Animal experiments

All rats were housed cages with a specific pathogen-free environment (12:12 h dark/light cycles) at constant temperature ( $22.5 \pm 1$  °C) and given ad libitum access to rodent chow and water. Ethical approval was obtained from Ataturk University-Ethical Committee (No: E.2100036488). 24 male wistar rats were acquired from Ataturk University Experimental Research Center.

All experimental groups were comprised of six rats each.

1. **Control group:** rats were given saline (0.9%, w/v)
2. **THA:** rats were given 200 mg/kg bw THA intraperitoneally, three times on the 0<sup>th</sup>, 2<sup>nd</sup> and 4<sup>th</sup> days of the experiment
3. **THA + TX1:** After THA-intoxication of rats, 50 mg/kg TX was administered for fourteen days by oral-gavage (from the 5<sup>th</sup> to the 18<sup>th</sup> days of the experiment) (Sun et al. 2014; Unver et al. 2019),
4. **THA + TX2:** After THA-intoxication of rats, 100 mg/kg TX was administered for fourteen days by oral-gavage (from the 5<sup>th</sup> to the 18<sup>th</sup> days of the experiment) (Sun et al. 2014).

Lethal hypoglycemia, hypopotassemia and kidney failure were prevented by supportive therapy (10% dextrose solution with 0.5 mL Lactate Ringer every twelve hours following each THA administration. Baraka et al. 2020; Ferah Okkay et al. 2021c). The schema of the experiment was presented in Fig. 1.

All rats were euthanized with sodium-thiopental (50 mg/kg, i.p.). The collected blood was stored and hepatic and hippocampal tissues were stored at  $-86$  °C for biochemical analysis and were kept in stabilization reagent for molecular analysis. Remaining tissues were stabilized in 10% FBS for histopathological and immunohistochemical analysis.

### Examination of behavioral alterations

The neurobehavioral analyses were performed in an isolated room at constant temperature.

#### Locomotor activity test (LAT) (Open field test)

The LAT test is widely used to determine the exploratory behavior and general activity of the rats and The LAT test was also utilized to analyze movement of rats and anxiety-like behaviours of rats. This test handles a

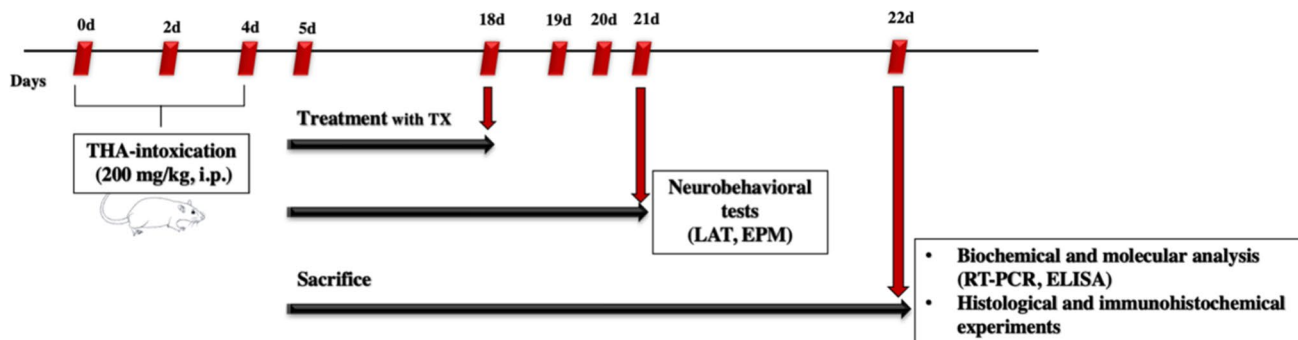


Fig. 1 The schema of the experimental design

camera (May Act 508) to calculate the rats' movement in the regions of a 42 cm × 42 cm × 42 cm open field box. The test was performed in a box that consisted of a black square floor with four vertical walls. The rats were positioned in the OFT box and allowed to move around freely for ten minute session (Ghobadi Pour et al. 2020). Time spent sedentary and total distance records were noted.

### Elevated plus-maze test (EPM)

EPM is a widespread used neurobehavioral test and has been affirmed to assess the anti-anxiety effects of pharmacological agents (Horii et al. 2018). The EPM platform (10 × 10 cm) comprised two enclosed and two open arms. The entire device was fixed at 50 cm above the ground. The rat was placed in the center of the maze, facing one of the closed arms, and was allowed to explore the open or closed arm of the maze for 5 min. The rat was considered as entering the open arm area when it placed its four paws on the open arm area. Increasing of numbers of open-arm entries and the duration spent in the open arms indicated that the rat had less anxiety. The number of entries into open arms were recorded for five minutes by EthoVision XT 10.0 monitoring software (Noldus Information Technology, Netherland).

### Biochemical analysis

Serum ammonia, alanine aminotransferase (ALT), aspartate aminotransferase (AST), alkaline phosphatase (ALP) and lactate dehydrogenase (LDH) concentrations were detected by ELISA kits (Elabscience, United States) Furthermore, glutathione (GSH), malondialdehyde (MDA), catalase (CAT) and ROS concentrations were determined in hippocampal and hepatic tissues by ELISA kits (Elabscience, United States, LSBio, United states, respectively). The ELISA analyses were conducted based on manufacturer's instructions (Ferah Okkay et al. 2021b). The absorbance was determined by spectrophotometer at 480 nm.

### Molecular analysis

Total RNA was extracted by RNeasy kit based on manufacturer's instructions and purified mRNA was used for cDNA synthesis as stated before (Ferah Okkay et al. 2021a). RT-PCR assays were carried out to verify gene expression (Okkay et al. 2021a, 2021b). Relative mRNA NF-κB, TNF-α, IL-1β, IL-10, caspase-3, Bax and Bcl-2 expression levels of hepatic and hippocampal tissues were determined by Rotor-Gene Q (QIAGEN). β-actin was used as a house-keeping gene and relative expressions of each protein were normalized to β-actin with the  $2^{-\Delta\Delta Ct}$  method. All primer sequences were provided in Table 1.

### Histological examinations

Histopathological analyses were performed as stated before (Ferah Okkay et al. 2021c). Tissue slides were visualized by hematoxylin and eosin (H&E) staining for histopathological experiments. Histopathological damage scores are presented in Table 2 (Rutherford et al. 2010; Yildiz et al. 2013).

### Immunostaining analyses

Immunostaining analyses were performed as stated before (Ferah Okkay et al. 2021c). Tissue-sections were evaluated with light microscope (Leica:DM-1000). The slides were incubated with primary antibody at 21 °C for 45 min. Immunoreactivity was assessed by a semi-quantitative four-grade scale (0: no reaction; 1: weak; 2: moderate; 3: strong immunoreactivity) and shown in Table 3 (Granados-Principal et al. 2015; Murtas et al. 2010).

### Statistical analyses

Obtained data was presented as mean ± standard deviation (SD). ELISA and RT-PCR results were analyzed by one-way ANOVA followed by Tukey's post hoc test

**Table 1** Sequence list of the primers used for RT-PCR

Genes	Forward Sequence (5'-3')	Reverse Sequence (3'-5')
<i>TNF-α</i>	CACACGAGACGCTGAAGTAG	AACAGTCTGGGAAGCTCTGA
<i>IL-1β</i>	TGCTGTGTGATTGCAGACAA	GTACAGCGTCCCAGTCATC
<i>IL-10</i>	TCAGCATATTGCCAGCAGTC	CAAAGGTTGGGTGTGGCTTA
<i>NF-κB</i>	CGAATGTAGACACGAAGCGT	CAACCAGGAAGCATAGACCG
<i>Caspase-3</i>	TGGACAACAACGAAACCTCC	CCAGGCACAGTATCTCTTGC
<i>Bax</i>	AGGGAGAGAGCACTGTTTCA	CTCTTGCCCTCAGTCATCAGC
<i>Bcl-2</i>	GTTTGCGTTGGCATTACGAG	GCCAAAATTAACCATGGCGG

Nf-κB: nuclear factor kappa B; Tnf-α, tumor necrosis factor alpha; IL-1β: interleukin 1β; IL-10: interleukin 10

**Table 2** Pathological evaluation of brain and liver. (Rutherford et al. 2010; Yildiz et al. 2013)

Liver pathological necrosis	Score	Definition
Hepatocellular necrosis around the vena centralis	0	None
	1	Mild
	2	Moderate
	3	Severe
Brain pathological necrosis	Score	Definition
Neuronal necrosis	0	None
	1	Mild
	2	Moderate
	3	Severe

( $p < 0.05$ ). Immunohistochemical results were subjected to Kruskal–Wallis with Mann–Whitney U post hoc test ( $p < 0.05$ ).

## Results

### LAT results

THA-intoxicated rats had a marked elevation in resting time, as well as a marked decline in total travel distance in contrast to control group. Inversely, a marked decline in resting time and an elevation in travel-distance were noticed in the TX-treated rats. The locomotor activity was similar in both TX treatment groups. In this study, TX treatment definitely enhanced the locomotor activity of rats (Fig. 2.).

### EPM results

In the course of examination, less access into the arms is thought as anxiety-like manners in rats. THA-intoxicated

**Table 3** Scoring system used for immunohistochemical identification of 8-OHdG and iNOS (Granados-Principal et al. 2015; Murtas et al. 2010)

IHC evaluation of 8-OHdG	Score	Intensity of staining
8-OHdG staining	0	Negative
	1	Weak
	2	Moderate
	3	Strong
IHC evaluation of iNOS	Score	Intensity of staining
iNOS staining	0	Negative
	1	Weak
	2	Moderate
	3	Strong

rats had a marked reduction in the entries into the open arms in comparison with the control group. According to the obtained data, TX-treatment significantly raised the open-arms entries as compared with THA-intoxicated rats. Similar to LAT test results, behavioral test results of EPM test proved that TX-treatment might return behavioural disability related THA (Fig. 2.).

### Biochemical results

THA-induced liver injury, reflecting the hepatotoxicity of THA, was demonstrated via significant increases in serum ammonia, ALT, AST, ALP and LDH concentrations (Figs. 3 and 4). Moreover, in hippocampal and hepatic tissues, compared with the control, the results showed that the levels of lipid peroxidation products (MDA and ROS) were elevated in the THA-intoxicated rats (Figs. 5 and 6).

The serum levels of ammonia, ALT, AST, ALP and LDH were markedly decreased in the TX groups showing that TX efficiently improved the THA-induced elevation in hepatic functions and oxidative stress via the decline in these parameters. THA led to a decrease in the hippocampus and liver activities of CAT and GSH. TX-treatment markedly increased the activity of CAT and GSH (Figs. 5 and 6).

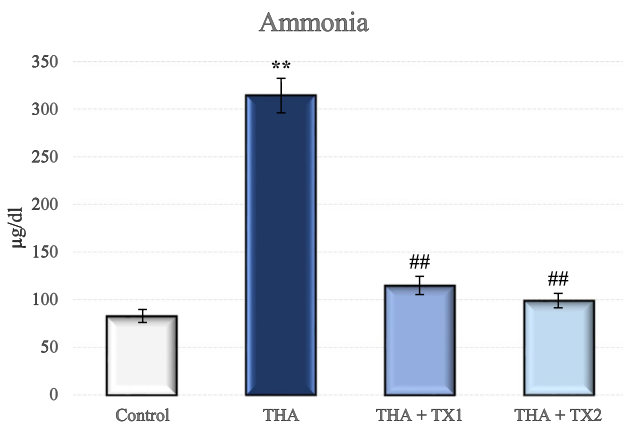
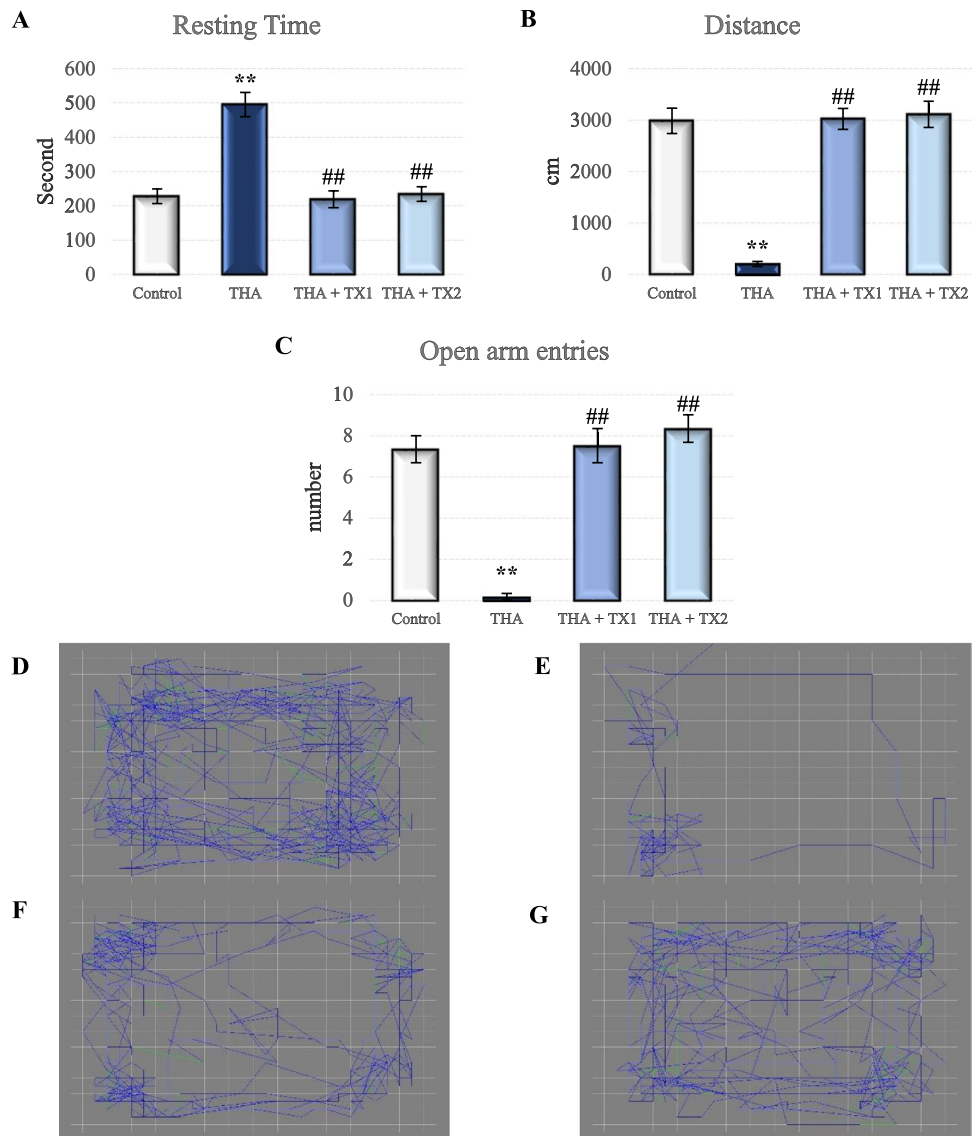
### Molecular results

TNF- $\alpha$ , NF- $\kappa$ B and IL-1 $\beta$  mRNA expressions in the hippocampal and hepatic tissue were significantly higher in the THA-intoxicated rats while mRNA expressions of these pro-inflammatory cytokines were decreased in the TX-treated rats as compared to THA-intoxicated rats (Figs. 7 and 8). IL-10 expressions were decreased in THA-intoxicated rats while mRNA expressions of IL-10 were increased in TX-treated rats. The hippocampal and hepatic tissue levels of caspase-3 and Bax were also markedly elevated while the levels of Bcl-2 were significantly declined in THA-intoxicated rats in contrast to control group. Rats in TX groups, exhibited declined mRNA expressions of the caspase-3 and Bax (Figs. 9 and 10). Moreover, Bcl-2 expressions were markedly increased in Tx-treated rats.

### Histopathological results

Histologically, the control group hippocampal sections showed a normal histological structure. In the hippocampal sections of the THA control group, gliosis with multiple focal areas, especially astrogliosis, was observed. Astrocytes appeared swollen with vesicular nuclei. In the hippocampal sections, there was a significant degenerated neuron reduction along with enlarged astrocytes in the treatment groups in comparison with the THA-intoxicated rats (Fig. 11).

**Fig. 2** Behavioural alterations of TX-treated rats in the LAT and EPM tests. The resting time was significantly decreased by TX as compared with THA-intoxicated rats. TX treatment decreased locomotor activity deficits. TX-treatment significantly raised the open-arms entries as compared with THA-intoxicated rats. (A) Resting time in LAT. (B) Total distance covered in LAT. (C) Open arm entry numbers in EPM. (D) LAT record of a rat in control group. (E) LAT record of a rat in THA group. (F) LAT record of a rat in THA + TX1 group. (G) LAT record of a rat in THA + TX2 group. Data are expressed as the means  $\pm$  SD. \*\*  $p < 0.001$  vs. control group, ##  $p < 0.001$  vs. THA group (n = 6). THA: Thioacetamide, TX: Taxifolin



**Fig. 3** Serum ammonia levels. The serum levels of ammonia were markedly decreased in the TX groups. Data are expressed as the means  $\pm$  SD. \*\*  $p < 0.001$  vs. control group, ##  $p < 0.001$  vs. THA group (n = 6). THA: Thioacetamide, TX: Taxifolin

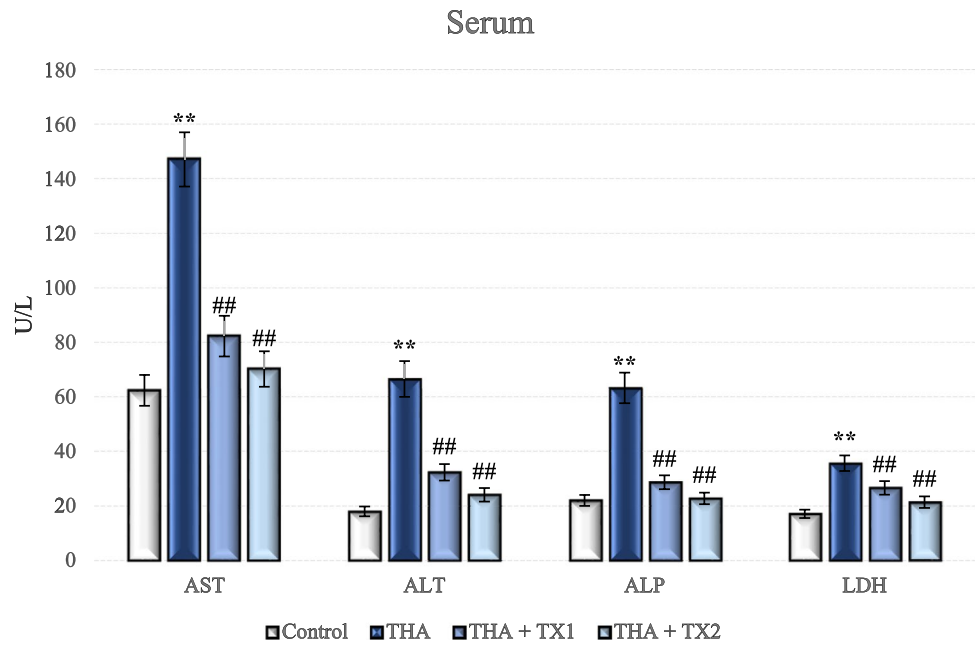
It was observed that rat liver sections in the control group had a typical structure with systematized, intact hepatic parenchyma and hepatocytes with regular structure. THA caused severe hepatotoxicity, manifested by high hepatocyte degeneration in the THA-intoxicated rats. TX-treatment provided mitigation of inflammatory cell infiltration and liver injury (Fig. 12).

### Immunohistochemical results

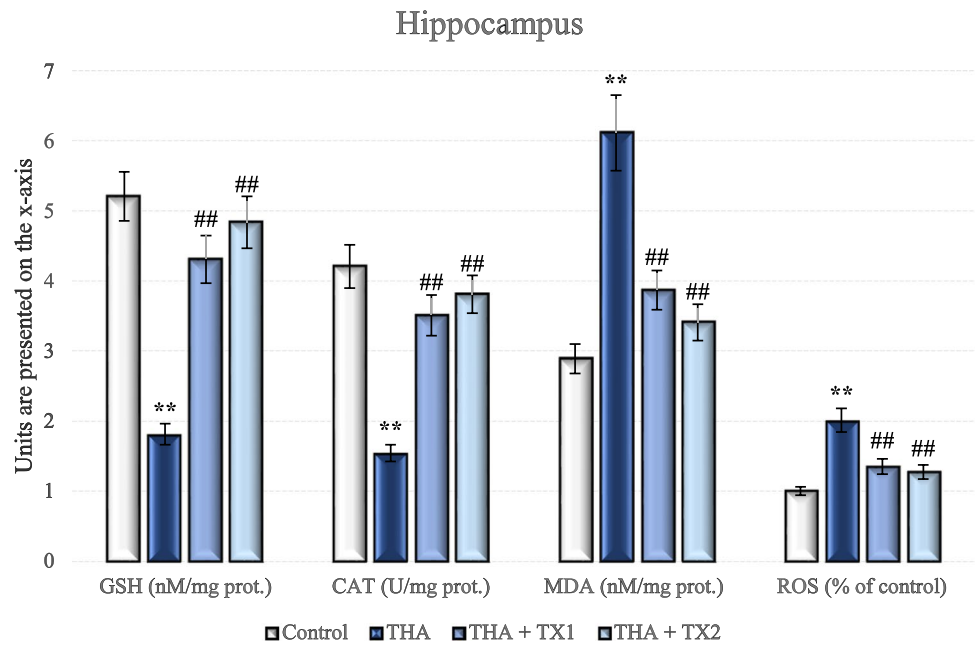
In the hepatic and hippocampal sections, 8-OHdG and iNOS immunoreactivity were assessed (Figs. 13, 14, 15 and 16). THA groups exhibited strong immunoreactivity while TX treated rat liver and hippocampal tissue sections showed reduced immunoreactivity in comparison to THA-intoxicated rats. Noticeably, TX-treatment led to a marked decline in the 8-OHdG and iNOS expression showing



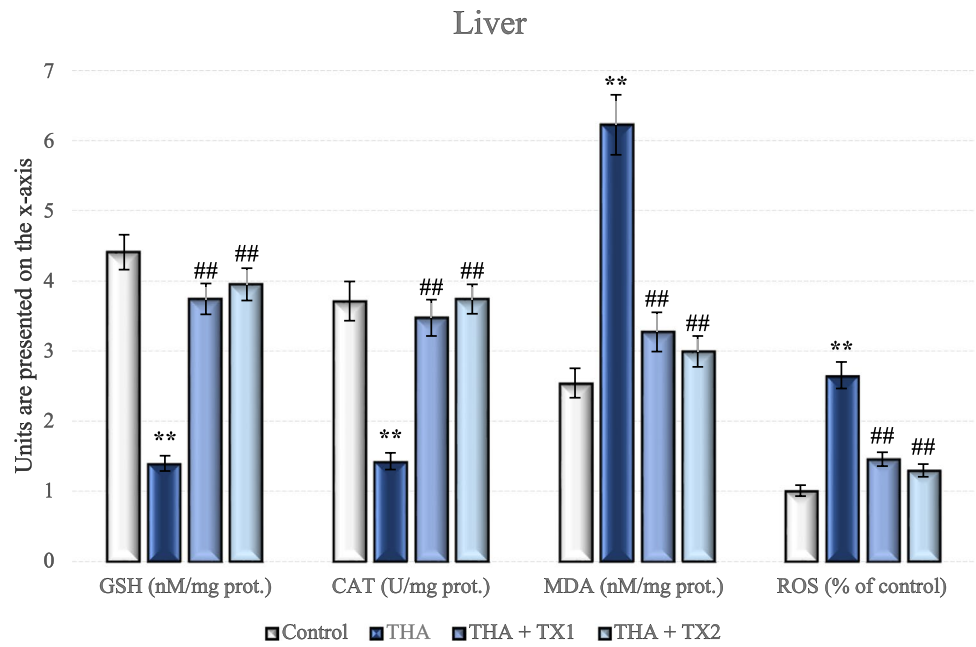
**Fig. 4** Serum hepatic injury marker levels. The serum levels of ALT, AST, ALP and LDH were markedly decreased in the TX groups. Data are expressed as the means  $\pm$  SD. \*\*  $p < 0.001$  vs. control group, ##  $p < 0.001$  vs. THA group (n=6). THA: Thioacetamide, TX: Taxifolin



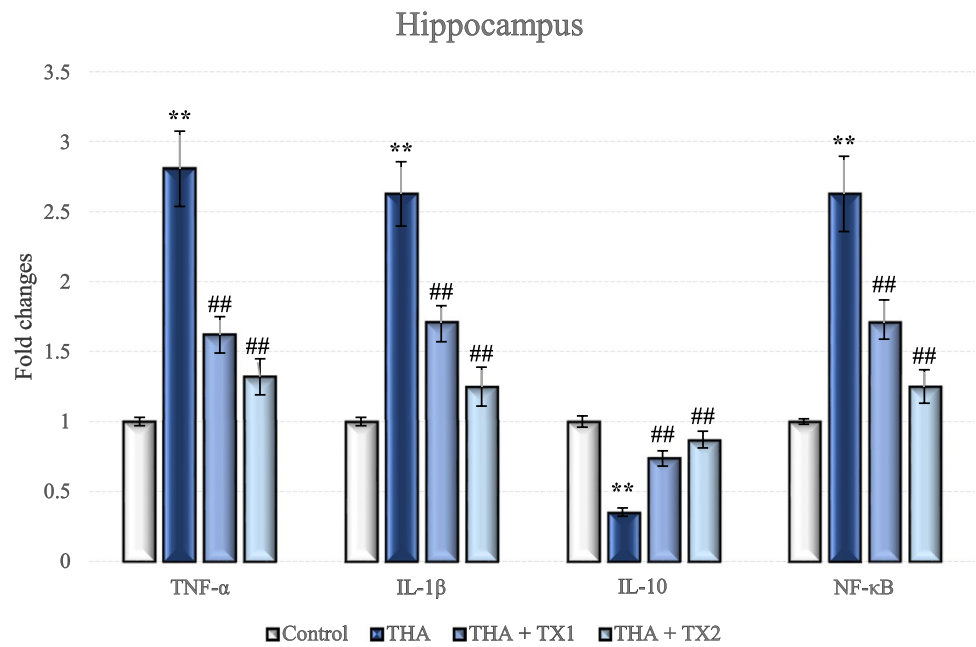
**Fig. 5** Oxidative stress markers in hippocampus. TX markedly reversed the THA-related oxidative stress via the decline in MDA and ROS and elevation in SOD and GSH levels. Data are expressed as the means  $\pm$  SD. \*\*  $p < 0.001$  vs. control group, ##  $p < 0.001$  vs. THA group (n=6). THA: Thioacetamide, TX: Taxifolin



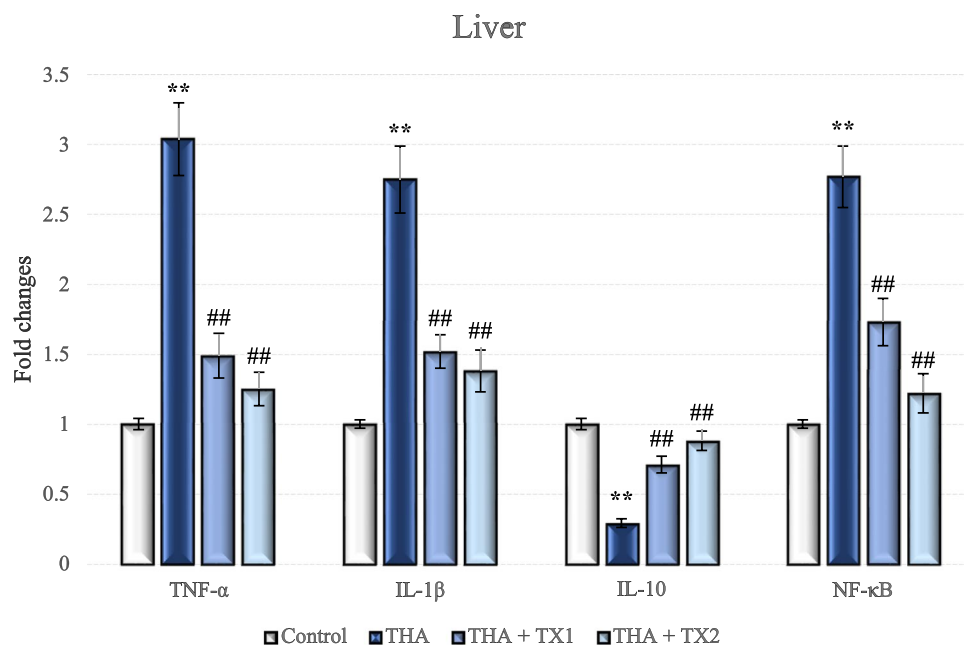
**Fig. 6** Oxidative stress markers in liver. TX markedly reversed the THA-related oxidative stress via the decline in MDA and ROS and elevation in SOD and GSH levels. Data are expressed as the means  $\pm$  SD. \*\*  $p < 0.001$  vs. control group, ##  $p < 0.001$  vs. THA group (n = 6). THA: Thioacetamide, TX: Taxifolin



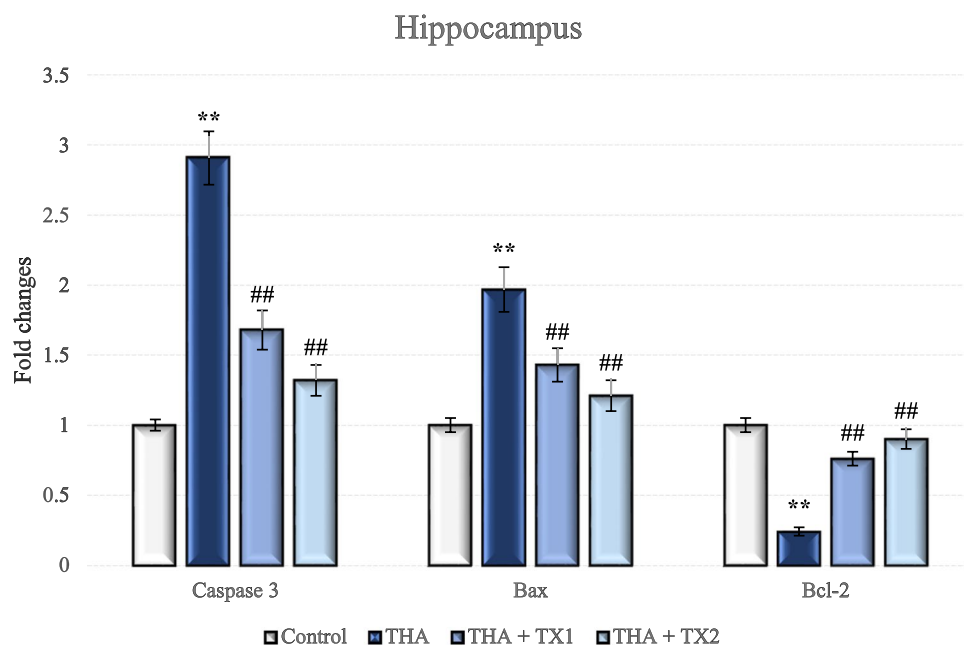
**Fig. 7** Inflammatory markers in hippocampus. The expression levels of TNF- $\alpha$ , NF- $\kappa$ B and IL-1 $\beta$  were decreased and IL-10 expression was increased in the TX-treated rats. Data are expressed as the means  $\pm$  SD. \*\*  $p < 0.001$  vs. control group, ##  $p < 0.001$  vs. THA group (n = 6). THA: Thioacetamide, TX: Taxifolin



**Fig. 8** Inflammatory markers in liver. The expression levels of TNF- $\alpha$ , NF- $\kappa$ B and IL-1 $\beta$  were decreased and IL-10 expression was increased in the TX-treated rats. Data are expressed as the means  $\pm$  SD. \*\*  $p < 0.001$  vs. control group, ##  $p < 0.001$  vs. THA group (n = 6). THA: Thioacetamide, TX: Taxifolin



**Fig. 9** Apoptotic markers in hippocampus. The caspase-3 and Bax expression levels were significantly decreased while Bcl-2 expression levels were increased with TX treatment. Data are expressed as the means  $\pm$  SD. \*\*  $p < 0.001$  vs. control group, ##  $p < 0.001$  vs. THA group (n = 6). THA: Thioacetamide, TX: Taxifolin



that TX reduced the intensity of the 8-OHdG and iNOS immunoreactivity.

## Discussion

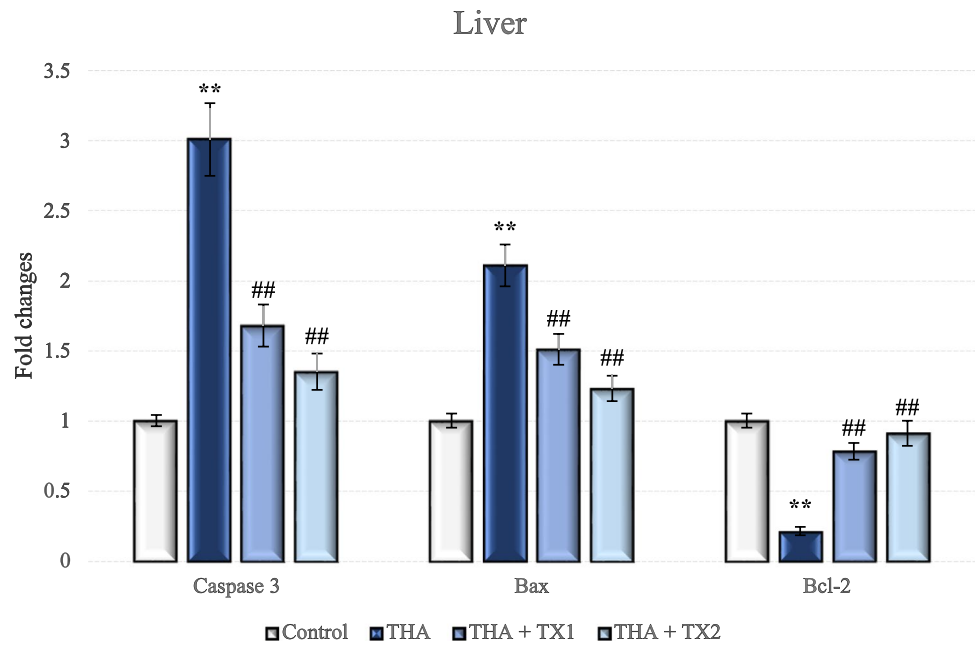
The current study reported that THA-intoxicated rats exhibited significant neuroinflammation, oxidative stress, apoptosis and eventual decrease in locomotor activity with behavioral deficits, which were evaluated by biochemical, molecular, histopathological, immunohistochemical,

LAT and EPM analyses. Our study results showed that TX restored liver function and locomotor activity by mitigating neuro- and hepato-inflammation, apoptosis and oxidative stress induced by THA.

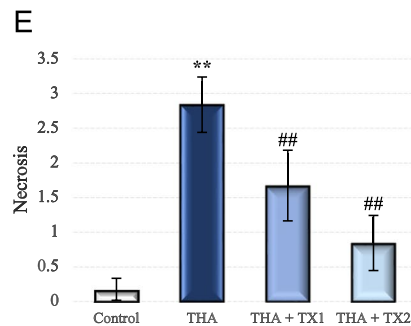
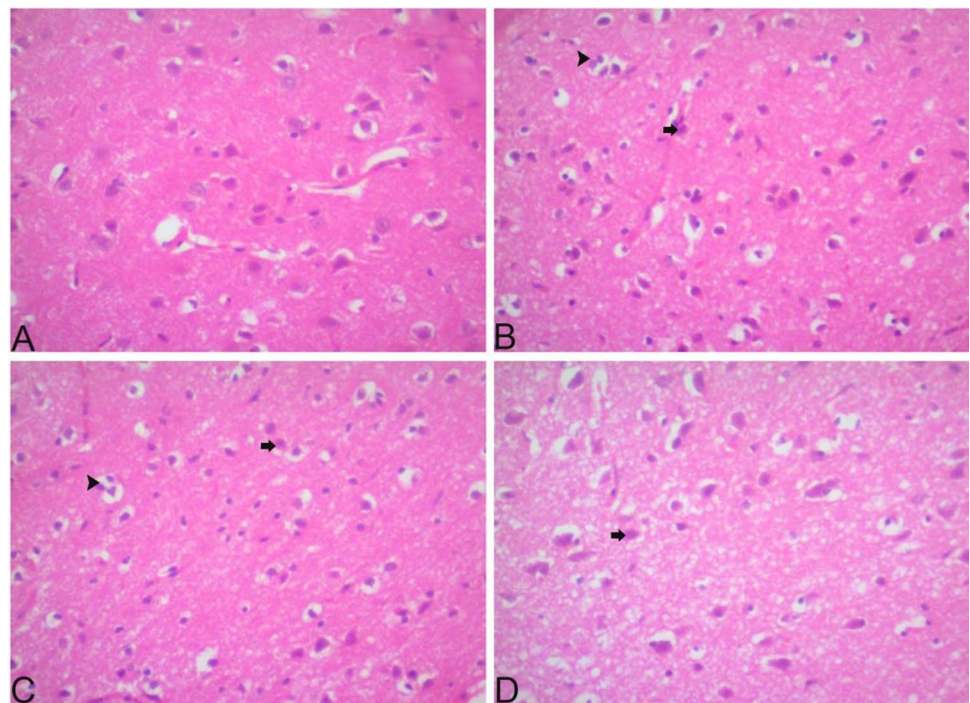
In the pathophysiology of HE, the blood–brain barrier-crossing potential of excessive ammonia is fairly high, which disrupts the brain metabolism and astrocyte structure and eventually leads to cognitive and motor symptoms (Mohammadian et al. 2019). Previous studies have shown that neuroinflammation together with hyperammonemia participates in the progression of mental



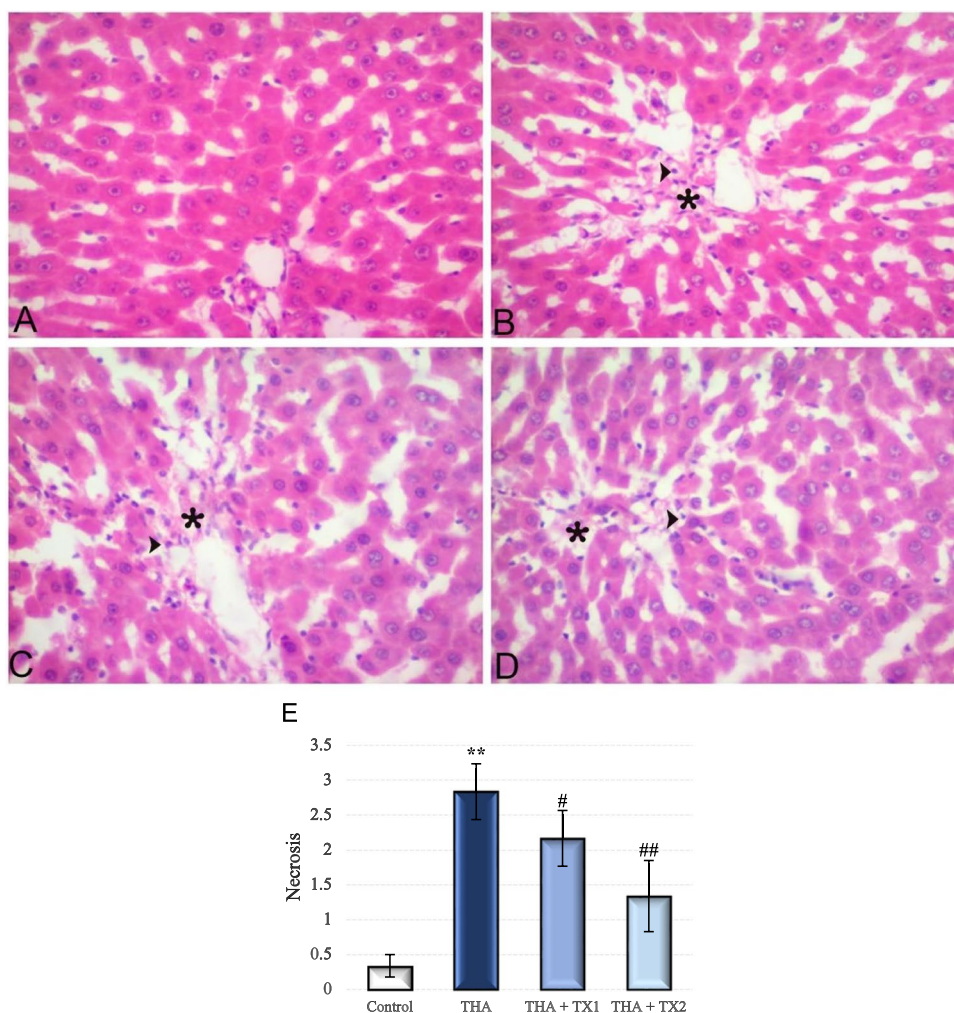
**Fig. 10** Apoptotic markers in liver. The caspase-3 and Bax expression levels were significantly decreased while Bcl-2 expression levels were increased with TX treatment. Data are expressed as the means  $\pm$  SD. \*\*  $p < 0.001$  vs. control group, ##  $p < 0.001$  vs. THA group (n=6). THA: Thioacetamide, TX: Taxifolin



**Fig. 11** Hippocampal histopathology of experimental groups (hematoxylin and eosin staining ( $\times 400$ )). Hippocampal tissues of control group rats demonstrated normal histological morphology. Necrosis and edema were detected in the hippocampal tissues of the THA-intoxicated rats. TX treatment mitigated neuronal injury (A) Control group (B) THA group (C) TX1 group; (D) TX2 group, (E) Necrosis Score Arrow: Necrosis, Arrowhead: Edema. Data are expressed as the means  $\pm$  SD. \*\*  $p < 0.001$  vs. control group, ##  $p < 0.001$  vs. THA group (n=6). THA: Thioacetamide, TX: Taxifolin



**Fig. 12** Liver histopathology of experimental groups (hematoxylin and eosin staining ( $\times 400$ )). Liver sections of control group rats had a normal morphological structure with intact hepatic parenchyma and hepatocytes. Liver tissues of THA-intoxicated rats displayed highly degenerated hepatocytes. TX-treatment provided mitigation of inflammatory cell infiltration and hepatic injury. Arrowhead: Necrosis. \*: Necrotic area (A) Control group (B) THA group (C) TX 1 group; (D) TX 2 group, (E) Necrosis Score. Data are expressed as the means  $\pm$  SD. \*\*  $p < 0.001$  vs. control group, #  $p < 0.05$  vs. THA group, ##  $p < 0.001$  vs. THA: Thioacetamide, TX: Taxifolin



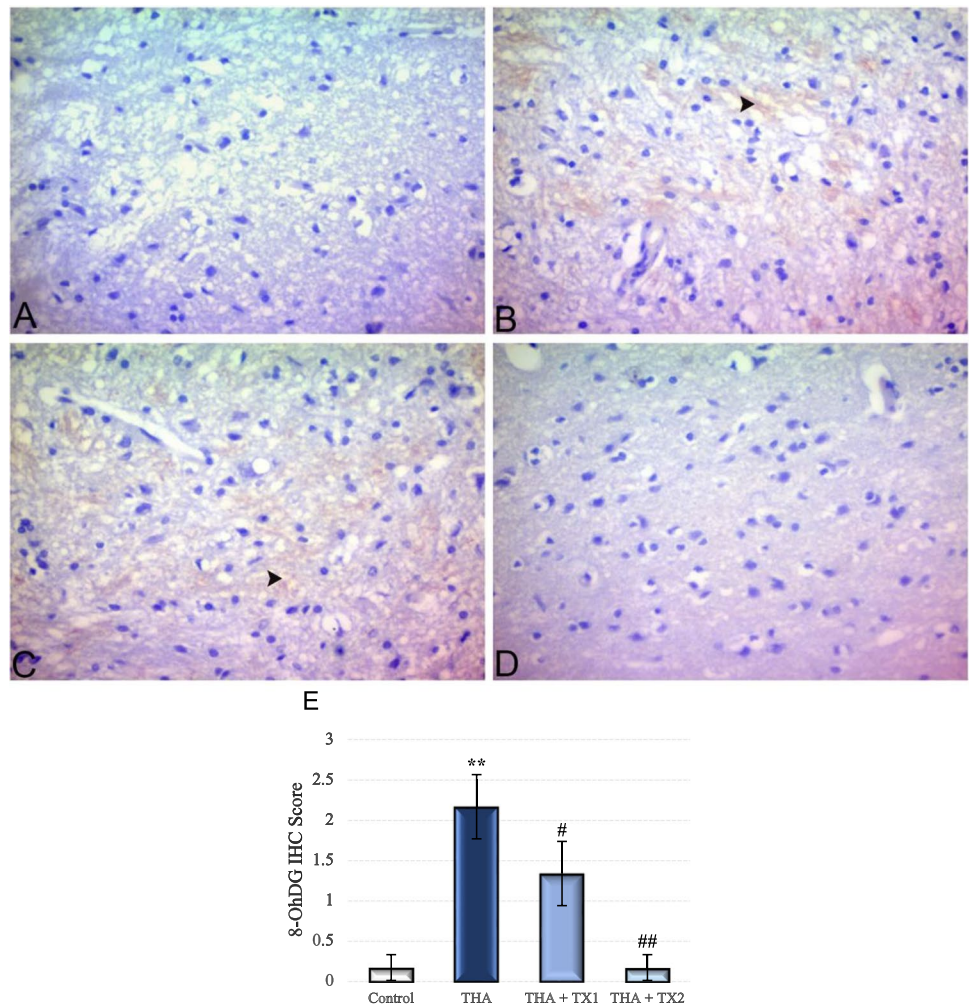
deficiency common in HE animal models in rats (Hajipour et al. 2021; Haussinger and Sies 2013). In our study, in rats intoxicated with THA, the impairment of locomotor and investigative functions was manifested by decreased entries to the maze arms. Consistent with current findings, together with evidence pointing to cognitive deficits in patients with HE, behavioural deficits were detected in rats with THA-induced HE (Abdel-Rafei et al. 2017; Mohammadian et al. 2019). TX treatment diminished the degenerating effects of THA on the central nervous system as manifested by declined ammonia levels and sheltered astroglia morphology in harmony with LAT and EPM data showing improved locomotor activity with entries to the maze arms. Saito et al. previously reported the neuroprotective effects of TX providing cognitive recovery in a mouse model of cerebral amyloid angiopathy (Saito et al.

2017). Another study in a mouse model of AD reported that 7-O-esters of TX improved short-term memory impairment. In that study, these TX esters demonstrated neuro-protective effects against oxytosis, ferroptosis and ATP depletion in the murine hippocampal neuron HT22 cell model (Gunesch et al. 2020).

It has been reported that HE disrupts hepatic enzyme levels, which is an important pathological step in the development of HE (Ferah Okkay et al. 2021c). THA-induced HE was manifested via the marked rise in the ammonia concentration concomitant by the elevation in ALT, AST, ALP and LDH levels. In rats given THA, hepatic enzymes such as AST, ALT, ALP and LDH indicate the severity of liver damage and highlight liver damage (Yogalakshmi et al. 2010). The increased activity of these hepatic enzymes as manifested by our results was confirmed by Khodir et al.



**Fig. 13** Immunohistochemical staining of 8-OHdG in experimental groups in hippocampus ( $\times 400$ ). 8-OHdG expression levels were markedly increased in THA-intoxicated rats while TX-treated rats showed marked decline in 8-OHdG expression. Arrowhead: Intensity of the immunoreactivity. (A) Control group (B) THA group (C) TX 1 group; (D) TX 2 group, (E) Immunohistochemistry score. Data are expressed as the means  $\pm$  SD. \*\*  $p < 0.001$  vs. control group, #  $p < 0.05$  vs. THA group, ##  $p < 0.001$  vs. THA group (n = 6). THA: Thioacetamide, TX: Taxifolin



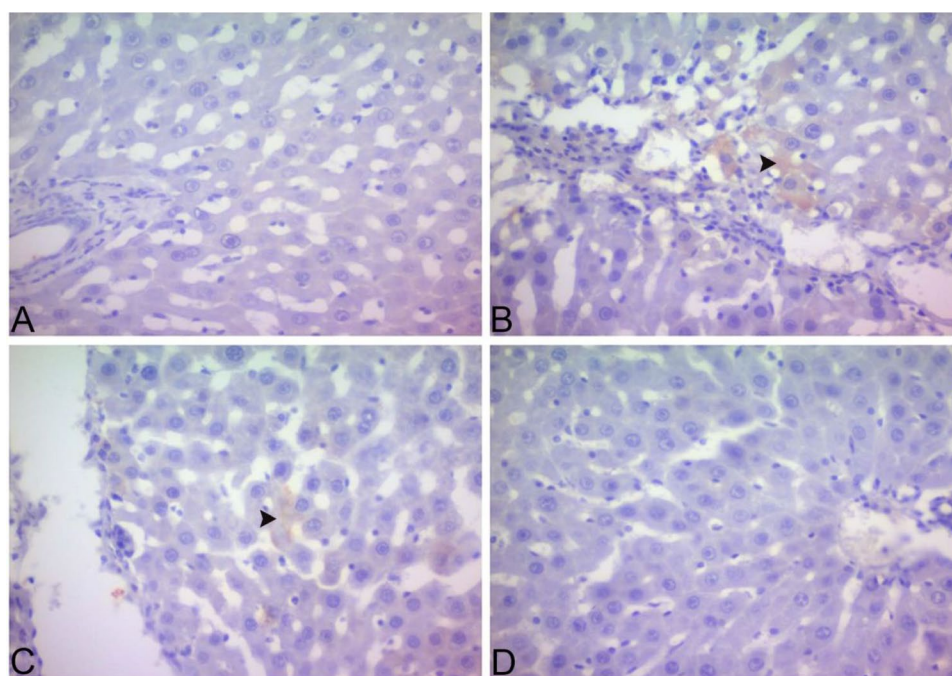
(Khodir and Said 2020). As stated in our study, TX treatment alleviated hepatic damage and provided a marked reduction in these hepatic enzyme activities in line with different hepatotoxicity studies (Yang et al. 2019), indicating its protection by maintaining the structural integrity of the hepatocellular membrane against hepatotoxins.

In reports, disturbed redox balance related to excessive ROS generation is closely linked to the mechanism of HE. In the current study, oxidative stress with disturbed redox balance was demonstrated in THA-intoxicated rats as manifested by a marked increase in ROS and MDA related to a marked decrease in GSH and CAT activities. Oxidative stress induced by THA via excessive production of ROS has been previously demonstrated by many studies (Chen et al. 2021; Elnfarawy et al. 2021). TX treatment suppressed MDA and strengthened the antioxidant defence mechanism

by increasing the activity of GSH and CAT. The protective effects of TX on the antioxidant mechanism reveal its role in cleaning free radicals (Ince et al. 2021). Besides increased oxidative stress, a marked increase was noticed in expressions of 8-OHdG in hippocampal/hepatic tissues of HE-induced rats. Our data have previously indicated that THA triggered DNA destruction with a higher expression level of 8-OHdG (Zargar et al. 2019). This report has demonstrated that TX down-regulated the 8-OHdG levels in line with previous reports (Eken et al. 2019).

Oxidative stress may lead to neuroinflammation by aggravating proinflammatory cytokine production, altering neurotransmission in the hippocampus and leading to subsequent cognitive deficits (Dadsetan et al. 2016; Lu et al. 2020). Cognitive and neurological disorders observed in HE-models have been associated with increased ammonia

**Fig. 14** Immunohistochemical staining of 8-OHdG in experimental groups in liver ( $\times 400$ ). 8-OHdG expression levels were markedly increased in THA-intoxicated rats while TX-treated rats showed marked decline in 8-OHdG expression. Arrowhead: Intensity of the immunoreactivity. (A) Control group (B) THA group (C) TX 1 group; (D) TX 2 group, (E) Immunohistochemistry score. Data are expressed as the means  $\pm$  SD. \*\*  $p < 0.001$  vs. control group, #  $p < 0.05$  vs. THA group, ##  $p < 0.001$  vs. THA group (n = 6). THA: Thioacetamide, TX: Taxifolin

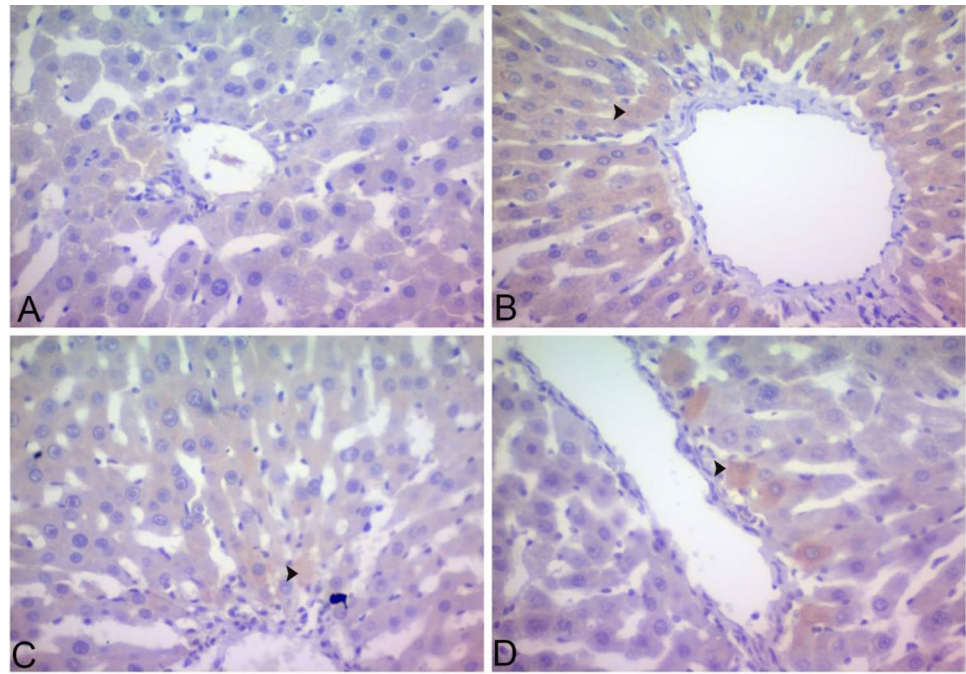


levels in the liver and brain, oxidative stress, and proinflammatory cytokines that exacerbate inflammation (Hernandez-Rabaza et al. 2016). Moreover, increased oxidative stress has been shown to activate NF- $\kappa$ B and the inflammatory signaling pathway, increasing the production of inflammatory mediators (Morgan and Liu 2011). In the current research, we have proved that NF- $\kappa$ B expression is triggered by THA-intoxication and that elevated NF- $\kappa$ B triggers the proinflammatory cytokine levels like TNF- $\alpha$ , IL-1 $\beta$ , and concomitant elevation of inflammatory mediators such as iNOS in the brain and liver. These data show that hepatic inflammation is accompanied by neuro-inflammation. The studies showing the suppressive effects of TX on both hepatic inflammation and neuronal

inflammation, along with its beneficial effects on oxidative damage, inspired us to investigate TX in hepatic encephalopathy (Ding et al. 2021; Inoue et al. 2019). The expression of TNF- $\alpha$ , IL-1 $\beta$  and iNOS was down-regulated while IL-10 was up-regulated in the hepatic and the hippocampal tissues with TX treatment, suggesting that TX attenuates hepato- and neuro-inflammation with its anti-inflammatory effect.

These findings were confirmed by histopathological analysis of THA-induced rats as demonstrated by marked astrocyte degeneration and swelling in hippocampal tissue and heavy hepatic necrosis, inflammation and fibrosis in liver tissues, which are in accordance with previous reports (El-Marasy et al. 2019; Ghobadi Pour et al. 2020).

**Fig. 15** Immunohistochemical staining of iNOS in experimental groups in hippocampus ( $\times 400$ ). iNOS expression levels were markedly increased in THA-intoxicated rats while TX-treated rats showed marked decline in 8-OHdG expression. Arrowhead: Intensity of the immunoreactivity. (A) Control group (B) THA group (C) TX 1 group; (D) TX 2 group, (E) Immunohistochemistry score. Data are expressed as the means  $\pm$  SD. \*\*  $p < 0.001$  vs. control group, #  $p < 0.05$  vs. THA group, ##  $p < 0.001$  vs. THA group (n = 6). THA: Thioacetamide, TX: Taxifolin



TX treatment returned the deleterious alterations in neuronal cells and recovered cell membrane permeability/integrity, as confirmed by hepatic function tests (Unver et al. 2019).

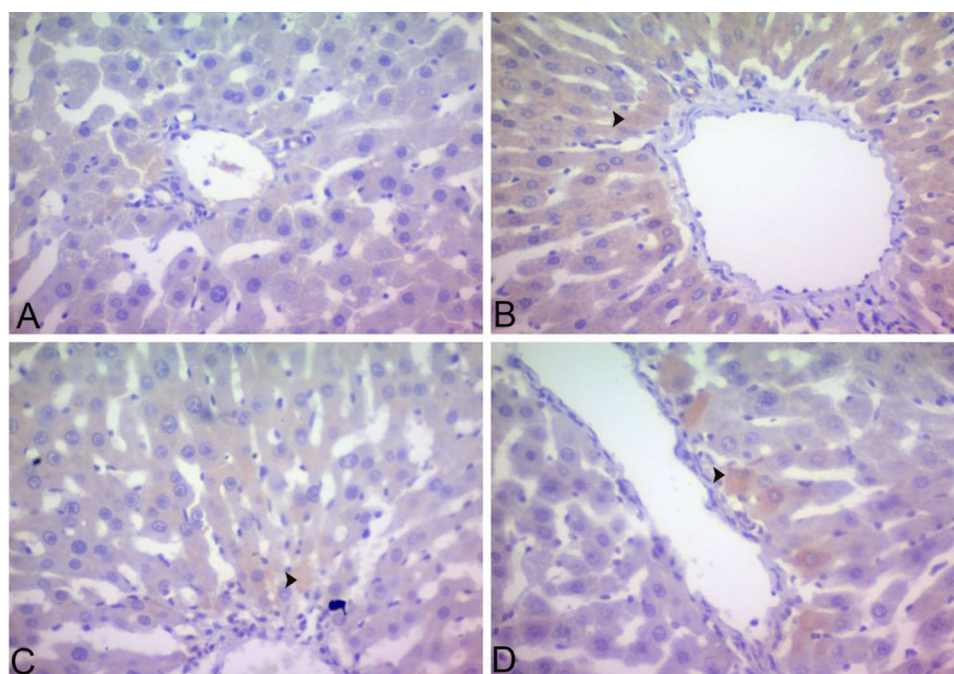
Membrane permeability increased by Bax activation induces apoptosis associated with mitochondrial stress, and Bax activation inhibits Bcl-2, which has a suppressive effect on apoptosis, and consequently promotes apoptosis. In addition, caspase-3, which acts as a key enzyme in apoptosis, triggers apoptosis. In the current study, caspase-3 and Bax levels increased while Bcl-2 levels decreased in rats intoxicated with THA (Chen et al. 2021). Considering the studies showing that TX suppresses apoptosis, including neuronal apoptosis, together with the importance of apoptosis in the formation of HE, it can be concluded it is very important to investigate TX in the HE model (Kim et al. 2017; Xie et al. 2017). Noteworthy, TX treatment counteracted apoptosis

by slowing the overexpression of caspase-3 and Bax and increasing the level of Bcl-2.

There is increasing evidence that antioxidants improve cognitive functions and motor impairments (Kontush and Schekatolina 2004). For example, it has been shown that a diet with high antioxidant content is beneficial in order to prevent age-related cognitive declines (Andres-Lacueva et al. 2005). The importance of the role of proinflammatory cytokines in neurodegenerative diseases is well-known (McAfoose and Baune 2009). Increased inflammation is also known to worsen cognitive damage and motor impairments, similar to the effects of apoptosis (Tiwari and Chopra 2012). Considering all these data, the research presented here provides evidence of the efficacy of TX supplementation in fixing the outcomes of HE by blocking cytokine-associated inflammation and Bcl-2, Bax and caspase-3-mediated apoptosis and oxidative stress with neurobehavioral disorders.



**Fig. 16** Immunohistochemical staining of iNOS in experimental groups in liver ( $\times 400$ ). iNOS expression levels were markedly increased in THA-intoxicated rats while TX-treated rats showed marked decline in 8-OHdG expression. Arrowhead: Intensity of the immunoreactivity. (A) Control group (B) THA group (C) TX 1 group; (D) TX 2 group, (E) Immunohistochemistry score. Data are expressed as the means  $\pm$  SD. \*\*  $p < 0.001$  vs. control group, #  $p < 0.05$  vs. THA group, ##  $p < 0.001$  vs. THA group ( $n = 6$ ). THA: Thioacetamide, TX: Taxifolin



**Acknowledgements** The authors are grateful to Prof. Dr. Ahmet Hacımuftuoğlu for his support during the experiments.

**Author contribution** Ufuk Okay: Investigation, Methodology, Resources; Writing-original draft, Visualization, Funding acquisition, Writing-review & editing. Irmak Ferah Okay: Funding acquisition, Data curation, Conceptualization, Validation, Writing-original draft, Writing-review & editing. Betül Cicek: Methodology. İsmail Çağrı Aydın: Investigation and Methodology. Mustafa Ozkaraca: Methodology and Writing-review & editing.

**Funding** This work was supported by Research Fund of the Ataturk University. (Project Number: TSA-2019–7527).

**Data availability** The data that support the findings of this study are available from the corresponding author upon reasonable request.

## Declarations

**Competing interest** The authors report no competing interest.

**Ethical approval** The experimental protocol was approved by Ataturk University-Ethical Committee (No: E.2100036488).

## References

- Abdel-Rafei M, Amin MM, Hasan HF (2017) Novel effect of Daflon and low-dose gamma-radiation in modulation of thioacetamide-induced hepatic encephalopathy in male albino rats. *Hum Exp Toxicol* 36:62–81
- Andres-Lacueva C, Shukitt-Hale B, Galli RL, Jauregui O, Lamuela-Raventos RM, Joseph JA (2005) Anthocyanins in aged blueberry-fed rats are found centrally and may enhance memory. *Nutr Neurosci* 8:111–120
- Baraka SM, Saleh DO, Ghaly NS, Melek FR, Gamal El Din AA, Khalil WKB, Said MM, Medhat AM (2020) Flavonoids from *Barnebydendron riedelii* leaf extract mitigate thioacetamide-induced hepatic encephalopathy in rats: The interplay of NF- $\kappa$ B/IL-6 and Nrf2/HO-1 signaling pathways. *Bioorg Chem* 105:104444
- Butterworth RF (2011) Hepatic encephalopathy: a central neuroinflammatory disorder? *Hepatology* 53:1372–1376
- Butterworth RF, Norenberg MD, Felipe V, Ferenci P, Albrecht J, Blei AT, Members of the ICoEMoHE (2009) Experimental models of hepatic encephalopathy: ISHEN guidelines. *Liver Int* 29:783–788.
- Chen X, Ding C, Liu W, Liu X, Zhao Y, Zheng Y, Dong L, Khatoun S, Hao M, Peng X, Zhang Y, Chen H (2021) Abscisic acid ameliorates oxidative stress, inflammation, and apoptosis in thioacetamide-induced hepatic fibrosis by regulating the NF-small ka, CyrillicB signaling pathway in mice. *Eur J Pharmacol* 891:173652



- Dadsetan S, Balzano T, Forteza J, Cabrera-Pastor A, Taoro-Gonzalez L, Hernandez-Rabaza V, Gil-Perotin S, Cubas-Nunez L, Garcia-Verdugo JM, Agusti A, Llansola M, Felipe V (2016) Reducing Peripheral Inflammation with Infliximab Reduces Neuroinflammation and Improves Cognition in Rats with Hepatic Encephalopathy. *Front Mol Neurosci* 9:106
- Ding C, Zhao Y, Chen X, Zheng Y, Liu W, Liu X (2021) Taxifolin, a novel food, attenuates acute alcohol-induced liver injury in mice through regulating the NF-kappaB-mediated inflammation and PI3K/Akt signalling pathways. *Pharm Biol* 59:868–879
- Eken H, Cimen O, Cimen FK, Kurnaz E, Yildirim M, Tasova V, Kurt N, Pehlivanoglu K, Onk D, Bilgin AO (2019) Effect of taxifolin on oxidative gastric injury induced by celiac artery ligation in rats. *Acta Cir Bras* 34:e201900404.
- El-Marasy SA, El Awdan SA, Abd-Elsalam RM (2019) Protective role of chrysin on thioacetamide-induced hepatic encephalopathy in rats. *Chem Biol Interact* 299:111–119
- Elfarawy AA, Nashy AE, Abozaid AM, Komber IF, Elweshahy RH, Abdelrahman RS (2021) Vinpocetine attenuates thioacetamide-induced liver fibrosis in rats. *Hum Exp Toxicol* 40:355–368
- Erceg S, Monfort P, Cauli O, Montoliu C, Llansola M, Piedrafita B, Felipe V (2006) Role of extracellular cGMP and of hyperammonemia in the impairment of learning in rats with chronic hepatic failure. *Therapeutic Implications Neurochem Int* 48:441–446
- Ferah Okkay I, Okkay U, Cicek B, Yilmaz A, Yesilyurt F, Mendil AS, Hacimuftuoglu A (2021b) Neuroprotective effect of bromelain in 6-hydroxydopamine induced in vitro model of Parkinson's disease. *Mol Biol Rep* 48:7711–7717
- Ferah Okkay I, Okkay U, Bayram C, Cicek B, Sezen S, Aydin IC, Mendil AS, Hacimuftuoglu A (2021a) Bromelain protects against cisplatin-induced ocular toxicity through mitigating oxidative stress and inflammation. *Drug Chem Toxicol*:1–8.
- Ferah Okkay I, Okkay U, Lutfi Gundogdu O, Bayram C, Sefa Mendil A, Sait Ertugrul M, Hacimuftuoglu A (2021c) Syringic acid protects against thioacetamide-induced hepatic encephalopathy: behavioral, biochemical, and molecular evidence. *Neurosci Lett*:136385.
- Ghobadi Pour M, Mirazi N, Alaei H, Radahmadi M, Rajaei Z, Monsef Esfahani A (2020) The effects of concurrent treatment of silymarin and lactulose on memory changes in cirrhotic male rats. *Bioimpacts* 10:177–186
- Gow AG (2017) Hepatic Encephalopathy. *Vet Clin North Am Small Anim Pract* 47:585–599
- Granados-Principal S, Liu Y, Guevara ML, Blanco E, Choi DS, Qian W, Patel T, Rodriguez AA, Cusimano J, Weiss HL, Zhao H, Landis MD, Dave B, Gross SS, Chang JC (2015) Inhibition of iNOS as a novel effective targeted therapy against triple-negative breast cancer. *Breast Cancer Res* 17:25
- Gunesch S, Hoffmann M, Kiermeier C, Fischer W, Pinto AFM, Maurice T, Maher P, Decker M (2020) 7-O-Esters of taxifolin with pronounced and overadditive effects in neuroprotection, anti-neuroinflammation, and amelioration of short-term memory impairment in vivo. *Redox Biol* 29:101378
- Hajipour S, Sarkaki A, Dianat M, Rashno M, Khorsandi LS, Farbood Y (2021) The effects of thymoquinone on memory impairment and inflammation in rats with hepatic encephalopathy induced by thioacetamide. *Metab Brain Dis* 36:991–1002
- Haussinger D, Sies H (2013) Hepatic encephalopathy: clinical aspects and pathogenetic concept. *Arch Biochem Biophys* 536:97–100
- Hernandez-Rabaza V, Cabrera-Pastor A, Taoro-Gonzalez L, Gonzalez-Usano A, Agusti A, Balzano T, Llansola M, Felipe V (2016) Neuroinflammation increases GABAergic tone and impairs cognitive and motor function in hyperammonemia by increasing GAT-3 membrane expression. Reversal by sulforaphane by promoting M2 polarization of microglia. *J Neuroinflammation* 13:83.
- Horii Y, McTaggart I, Kawaguchi M (2018) Testing Animal Anxiety in Rats: Effects of Open Arm Ledges and Closed Arm Wall Transparency in Elevated Plus Maze Test. *J Vis Exp*.
- Ince S, Ozer M, Kadioglu BG, Kuzucu M, Ozkaraca M, Gezer A, Suleyman H, Cetin N (2021) The effect of taxifolin on oxidative ovarian damage and reproductive dysfunctions induced by antipsychotic drugs in female rats. *J Obstet Gynaecol Res* 47:2140–2148
- Inoue T, Saito S, Tanaka M, Yamakage H, Kusakabe T, Shimatsu A, Ihara M, Satoh-Asahara N (2019) Pleiotropic neuroprotective effects of taxifolin in cerebral amyloid angiopathy. *Proc Natl Acad Sci U S A* 116:10031–10038
- Khodir AE, Said E (2020) Nifuroxazide attenuates experimentally-induced hepatic encephalopathy and the associated hyperammonemia and cJNK/caspase-8/TRAIL activation in rats. *Life Sci* 252:117610
- Kim A, Nam YJ, Lee CS (2017) Taxifolin reduces the cholesterol oxidation product-induced neuronal apoptosis by suppressing the Akt and NF-kappaB activation-mediated cell death. *Brain Res Bull* 134:63–71
- Kontush K, Schekatolina S (2004) Vitamin E in neurodegenerative disorders: Alzheimer's disease. *Ann N Y Acad Sci* 1031:249–262
- Liu Z, Zhu P, Zhang L, Xiong B, Tao J, Guan W, Li C, Chen C, Gu J, Duanmu J, Zhang W (2018) Autophagy inhibition attenuates the induction of anti-inflammatory effect of catalpol in liver fibrosis. *Biomed Pharmacother* 103:1262–1271
- Lu L, Wu C, Lu BJ, Xie D, Wang Z, Bahaji Azami NL, An YT, Wang HJ, Ye G, Sun MY (2020) BabaoDan cures hepatic encephalopathy by decreasing ammonia levels and alleviating inflammation in rats. *J Ethnopharmacol* 249:1123
- McAfoose J, Baune BT (2009) Evidence for a cytokine model of cognitive function. *Neurosci Biobehav Rev* 33:355–366
- McMillin M, Frampton G, Thompson M, Galindo C, Standford H, Whittington E, Alpini G, DeMorrow S (2014) Neuronal CCL2 is upregulated during hepatic encephalopathy and contributes to microglia activation and neurological decline. *J Neuroinflammation* 11:121
- Mohammadian F, Firouzjaei MA, Haghani M, Shabani M, Shid Moosavi SM, Mohammadi F (2019) Inhibition of inflammation is not enough for recovery of cognitive impairment in hepatic encephalopathy: Effects of minocycline and ibuprofen. *Brain Res Bull* 149:96–105
- Montes-Cortes DH, Novelo-Del Valle JL, Olivares-Corichi IM, Rosas-Barrientos JV, Jara LJ, Cruz-Dominguez MP (2018) Impact of intestinal mannitol on hyperammonemia, oxidative stress and severity of hepatic encephalopathy in the ED. *Am J Emerg Med* 36:1570–1576
- Morgan MJ, Liu ZG (2011) Crosstalk of reactive oxygen species and NF-kappaB signaling. *Cell Res* 21:103–115
- Murtas D, Piras F, Minerba L, Ugalde J, Floris C, Maxia C, Demurtas P, Perra MT, Sirigu P (2010) Nuclear 8-hydroxy-2'-deoxyguanosine as survival biomarker in patients with cutaneous melanoma. *Oncol Rep* 23:329–335
- Okkay U, Ferah Okkay I, Aydin IC, Bayram C, Ertugrul MS, Gezer A, Hacimuftuoglu A (2021a) Effects of *Achillea millefolium* on cisplatin induced ocular toxicity: an experimental study. *Cutan Ocul Toxicol*:1–7.
- Okkay U, Ferah Okkay I, Cicek B, Aydin IC, Ertugrul MS, Bayram C, Senyayla S, Sezen S, Mendil AS, Guven L, Hacimuftuoglu A (2021b) *Achillea millefolium* alleviates testicular damage in paclitaxel-intoxicated rats via attenuation of testicular oxido-inflammatory stress and apoptotic responses. *Andrologia* 53:e14028.
- Park SY, Kim HY, Park HJ, Shin HK, Hong KW, Kim CD (2016) Concurrent Treatment with Taxifolin and Cilostazol on the Lowering of beta-Amyloid Accumulation and Neurotoxicity via the Suppression of P-JAK2/P-STAT3/NF-kappaB/BACE1 Signaling Pathways. *PLoS One* 11:e0168286.

- Randolph C, Hilsabeck R, Kato A, Kharbanda P, Li YY, Mapelli D, Ravdin LD, Romero-Gomez M, Stracciari A, Weissenborn K, International Society for Hepatic E, Nitrogen M (2009) Neuropsychological assessment of hepatic encephalopathy: ISHEN practice guidelines. *Liver Int* 29:629–635.
- Rutherford M, Biarge MM, Allsop J, Counsell S, Cowan F (2010) MRI of perinatal brain injury. *Pediatr Radiol* 40:819–833
- Saito S, Yamamoto Y, Maki T, Hattori Y, Ito H, Mizuno K, Harada-Shiba M, Kalaria RN, Fukushima M, Takahashi R, Ihara M (2017) Taxifolin inhibits amyloid-beta oligomer formation and fully restores vascular integrity and memory in cerebral amyloid angiopathy. *Acta Neuropathol Commun* 5:26
- Sun X, Chen RC, Yang ZH, Sun GB, Wang M, Ma XJ, Yang LJ, Sun XB (2014) Taxifolin prevents diabetic cardiomyopathy in vivo and in vitro by inhibition of oxidative stress and cell apoptosis. *Food Chem Toxicol* 63:221–232
- Sun X, Lv Y, Huang L, Gao H, Ren C, Li J, Bie M, Li W, Koike K, So KF, Xiao J (2020) Pro-inflammatory cytokines serve as communicating molecules between the liver and brain for hepatic encephalopathy pathogenesis and Lycium barbarum polysaccharides protection. *J Ethnopharmacol* 248:112357
- Sunil C, Xu B (2019) An insight into the health-promoting effects of taxifolin (dihydroquercetin). *Phytochemistry* 166:112066
- Tanaka M, Saito S, Inoue T, Satoh-Asahara N, Ihara M (2019) Novel Therapeutic Potentials of Taxifolin for Amyloid-beta-associated Neurodegenerative Diseases and Other Diseases: Recent Advances and Future Perspectives. *Int J Mol Sci* 20.
- Tiwari V, Chopra K (2012) Attenuation of oxidative stress, neuroinflammation, and apoptosis by curcumin prevents cognitive deficits in rats postnatally exposed to ethanol. *Psychopharmacology* 224:519–535
- Topal F, Nar M, Gocer H, Kalin P, Kocyigit UM, Gulcin I, Alwasel SH (2016) Antioxidant activity of taxifolin: an activity-structure relationship. *J Enzyme Inhib Med Chem* 31:674–683
- Unver E, Tosun M, Olmez H, Kuzucu M, Cimen FK, Suleyman Z (2019) The Effect of Taxifolin on Cisplatin-Induced Pulmonary Damage in Rats: A Biochemical and Histopathological Evaluation. *Mediators Inflamm* 2019:3740867
- Wang YH, Wang WY, Chang CC, Liou KT, Sung YJ, Liao JF, Chen CF, Chang S, Hou YC, Chou YC, Shen YC (2006) Taxifolin ameliorates cerebral ischemia-reperfusion injury in rats through its anti-oxidative effect and modulation of NF-kappa B activation. *J Biomed Sci* 13:127–141
- Xie X, Feng J, Kang Z, Zhang S, Zhang L, Zhang Y, Li X, Tang Y (2017) Taxifolin protects RPE cells against oxidative stress-induced apoptosis. *Mol vis* 23:520–528
- Yang CL, Lin YS, Liu KF, Peng WH, Hsu CM (2019) Hepatoprotective Mechanisms of Taxifolin on Carbon Tetrachloride-Induced Acute Liver Injury in Mice. *Nutrients* 11.
- Yildiz O, Can Z, Saral O, Yulug E, Ozturk F, Aliyazicioglu R, Canpolat S, Kolayli S (2013) Hepatoprotective potential of chestnut bee pollen on carbon tetrachloride-induced hepatic damages in rats. *Evid Based Complement Alternat Med* 2013:461478.
- Yogalakshmi B, Viswanathan P, Anuradha CV (2010) Investigation of antioxidant, anti-inflammatory and DNA-protective properties of eugenol in thioacetamide-induced liver injury in rats. *Toxicology* 268:204–212
- Zargar S, Alonazi M, Rizwana H, Wani TA (2019) Resveratrol Reverses Thioacetamide-Induced Renal Assault with respect to Oxidative Stress, Renal Function, DNA Damage, and Cytokine Release in Wistar Rats. *Oxid Med Cell Longev* 2019:1702959
- Zhan ZY, Wu M, Shang Y, Jiang M, Liu J, Qiao CY, Ye H, Lin YC, Piao MH, Sun RH, Zhang ZH, Jiao JY, Wu YL, Nan JX, Lian LH (2021) Taxifolin ameliorate high-fat-diet feeding plus acute ethanol binge-induced steatohepatitis through inhibiting inflammatory caspase-1-dependent pyroptosis. *Food Funct* 12:362–372

**Publisher's note** Springer Nature remains neutral with regard to jurisdictional claims in published maps and institutional affiliations.